

Ameliorative Role of *Moringa Oleifera* against Gamma Radiation and Mercury Induced Nephrotoxicity in Swiss Albino Mice

Manisha Agarwal ¹, Manoj Kumar ², Archana Purohit ³,
Aruna Chakrawarti ⁴, R.K. Purohit ⁵

¹ Corresponding Author

Radiation Biology Laboratory, Govt. Dungar College, Bikaner, Rajasthan, India

Abstract

Herbal plants and products represent important source of natural antioxidant and offer an alternative to synthetic protectors. *Moringa oleifera*, a herbal medicinal plant has been screen for their radioprotective activity. For the purpose of study male Swiss albino mice were divided into seven groups. The mice were exposed to gamma radiation (2.5 Gy and 5.0 Gy) and also provided mercuric chloride (0.5 ppm) both separately and combined. The herbal radioprotector *Moringa* was given to experimental groups after irradiation and mercury treatment. Animals were autopsied at post treatment interval of 1, 2, 4, 7, 14 and 28 days. After sacrificing the animal's histopathology of kidney was observed. Renal glomeruli and tubules depicted degenerative changes and changes were more pronounced in combined treatment groups. *Moringa* treated groups demonstrated early and fast onset of recovery in comparison to non-*Moringa* treated groups. Radioprotective efficacy of MOE was due to presence of various bioactive compound.

Keywords: Radiation, Mercury, Kidney, Mice

Introduction

Since the 1890s, scientists have known about radiation they have developed a wide variety of uses for radiation to benefit humankind. Today, radiation is used in medicine, academics, and industry, as well as for generating electricity. In addition, radiation has useful applications in such areas as agriculture, archaeology (carbon dating), space exploration, law enforcement, geology (including mining), and many others. Radiation sickness, also known as Acute Radiation Syndrome (ARS), is caused by a high dose of radiation. The severity of illness depends on the amount (or dose) of radiation. Accidental or intentional exposure to high doses of radiation symptoms may include nausea, fatigue, vomiting, and diarrhoea. Symptoms such as hair loss or skin burns may appear in weeks. Radiation exposure to semi lethal and lethal doses of gamma rays disrupt the organization of DNA and the cellular homeostasis.

Since mercury is present in the environment in such a ubiquitous manner, it is virtually impossible for humans to avoid exposure to some form of mercury. In addition to environmental exposure, individuals may be exposed to Hg from dental amalgams, medicinal treatments (including vaccinations), and/or dietary sources.

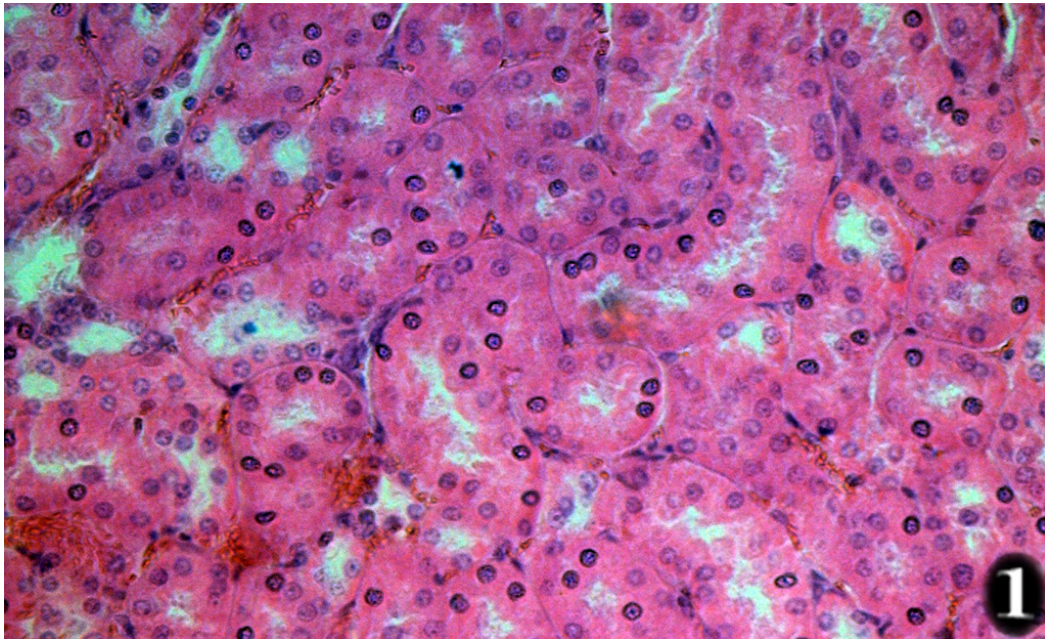
All plant parts of *Moringa oleifera* are traditionally used for different purposes, but leaves are generally the most used in particular, they are used in human nutrition and in the traditional medicine. Leaves are rich in protein, mineral, beta-carotene and antioxidant compounds, Moringa leaves are added to food preparations as integrators of the diet. In traditional medicine, these leaves are used to treat several ailments including malaria, typhoid fever, parasitic diseases, arthritis, swellings, cuts, diseases of the skin, Genito-urinary ailments, hypertension and diabetes. They are also used to elicit lactation and boost the immune system (to treat HIV/AIDS related symptoms), as well as cardiac stimulants and contraceptive remedy. Therefore, present study was undertaken to evaluate protective role of moringa against radiation and mercury induced nephrotoxicity.

Materials and Methods

The adult healthy male Swiss albino mice were procured and maintained at animal house of Govt. Dungar College, Bikaner (registration no.1066/go/re/s/07/CPSEA) and provided balanced mice feed and water *ad libitum*. As to investigate protective effect of *Moringa oleifera* in mice kidney against gamma radiation (2.5 Gy and 5.0 Gy) and mercuric chloride (0.5 ppm) alone and in combination also, the animals were divided into seven groups, (control and experimental). Group I was serving as normal and sham irradiated. Group II to IV were irradiated and treated with mercuric chloride and group V to VII were treated with *Moringa oleifera* extract along with the doses of radiation and mercury. The experimental animals were provided oral doses of *Moringa oleifera* (150 mg/kg body weight) from seven days prior to irradiation. A minimum of five animals from each group were sacrificed by cervical dislocation and autopsied at each post treatment intervals of 1, 2, 4, 7, 14, 28 days. After sacrificing the animals, pieces of Kidney were fixed in Bouin's fixative for 24 hours. The tissues were washed in water to remove excess of fixative, dehydrated in graded alcohol series, cleared in xylene and embedded in paraffin wax, Sections were cut at 5 μ m and stained in Harris hematoxylin and alcoholic eosin.

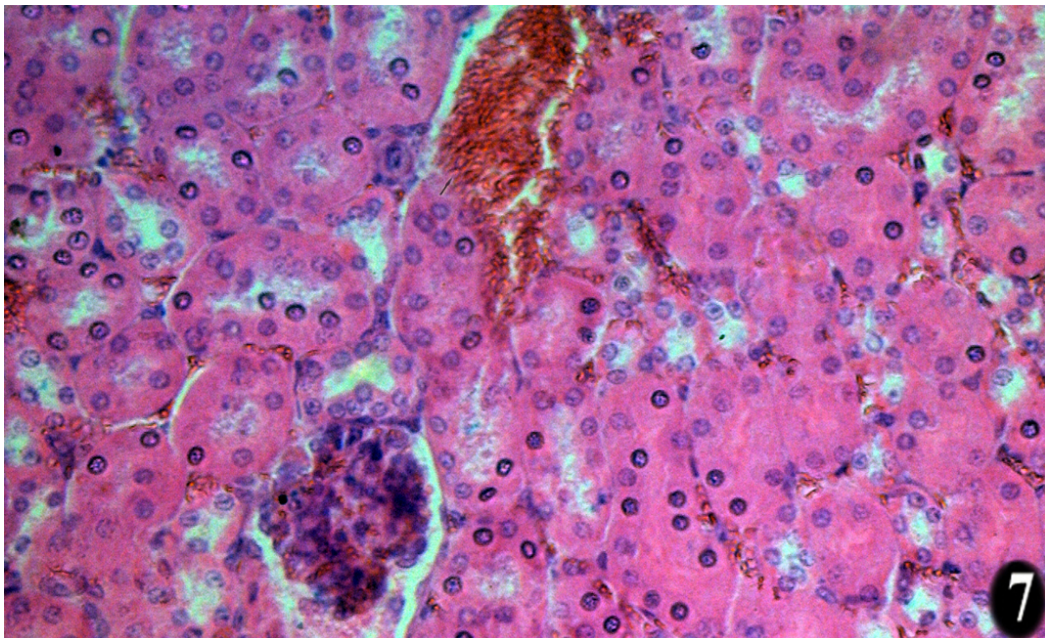
Results

Renal architecture was prominently damaged by the radiation treatment with both doses. Higher dose of radiation manifest greater degree of radio lesions. which showed in kidney histology Cytoplasmic degranulation, vacuolation were observed. The pycnotic nuclei increase in number, glomeruli become constricted. The renal capsule appeared distorted. After day 1 of autopsy degenerative changes in renal glomeruli and tubular cells seems to become evident. After day 2 of treatment leucocytic infiltration and hyperaemia was also observed. The changes in kidney cells become more severe up to day 14, after that the signs of recovery become evident at day 28 of treatment. Combined treatment group of radiation and mercury showed marked increase in severity of damage. The moringa treated groups showed early recovery and renal epithelium glomeruli and tubules recovered earlier after day 7 of treatment. On day 14, autopsy of the moringa treated group signs of recovery were appeared to reached at almost normal. Moringa provide protection from oxidative damage and causes fast recovery in comparison to non-drug treated group shows the radioprotective efficacy of Moringa.

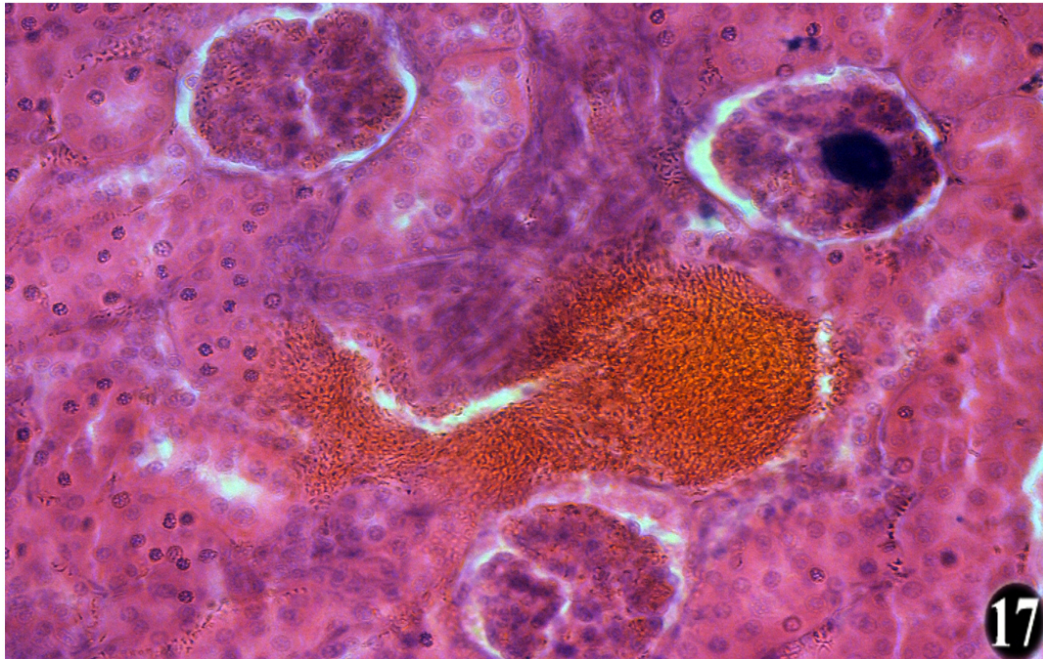


Sham irradiated animals showing normal renal architecture cytoplasmic, nuclear and tubular structures.

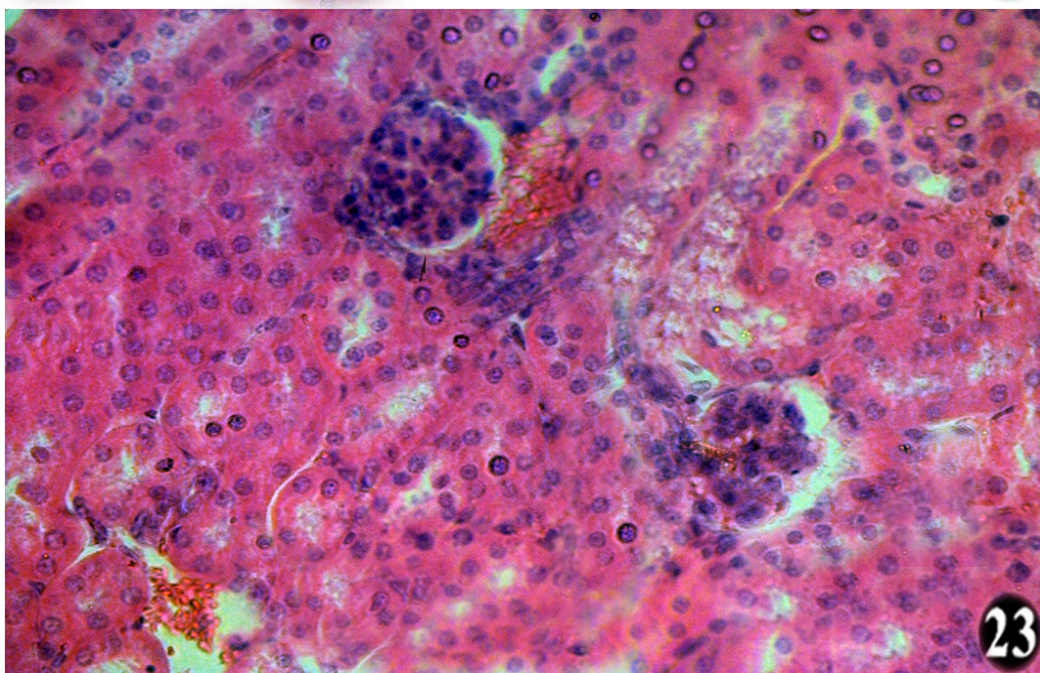
After 7 days of mercuric chloride treatment depicting distortion of renal architecture, cytoplasmic degeneration and vacuolation mild interstitial inflammation and glomerulo-nephritis.



After 17 days of gamma ray exposure (5.0 Gy) exhibiting crowding of glomeruli and hydropic degeneration in the cortex. Pycnotic nuclei in the tubular cells are persisted.



After 23 days (2.5 Gy + MC) representing a completely distorted glomerulus with wide spread cytoplasmic degranulation and vacuolation.



Discussion

Histopathological examination of renal tissues following ionising radiation revealed the occurrence of glomerular lesions including sclerosis and necrosis as well as hyperplasia of mesangial cells located in the glomerular tuft between capillary loops. Tubular lesions including necrosis were also observed, while there was inflammatory cell infiltration of the interstitial spaces. The EGTI pathology scoring of

the renal lesions, however, showed that the tubular portions of the nephrons appeared to be most affected by IR.

Interestingly, our findings showed significant improvement in the appearance of renal histology in rats that were pre-treated with the *Moringa oleifera* fraction. Rats taking either dose of the extract showed fewer glomerular lesions and milder inflammation which was also reflected in better EGTI indices. The tissue protective ability of the extract was also indicated in the dose-dependent reduction in serum levels of BUN and creatinine in rats pre-treated with either dose of the extract. This shows that more glomeruli were preserved when rats were fed with *M. oleifera*, thus retaining their filtration capacities and ensuring the excretion of urea and creatinine through urine (Corbett, 2008)(1).

In the last years, medicinal plants are widely used throughout the world, due to their potent pharmacological activities, low toxicity and economic viability when compared with the synthetic drugs (Pracheta et al., 2011)(2). *Moringa oleifera* (MO) is one of these plants which have many medicinal and nutritional properties associated with the presence of many functional bioactive compounds (Ma et al., 2020)(3).

Sreelatha and Padma (2009)(4) evaluated the antioxidant activity of Moringa leaves collected in India in two stages of maturity. The analysis revealed only minor, but significant; differences in the two maturity stages, mature and tender leaves, for the DPPH scavenging activity, superoxide scavenging activity, nitric oxide scavenging activity and for lipid peroxidation inhibition.

Verma et al. (2009)(5) examined the effects of administration of 50 and 100 mg/kg bw/day of ethyl acetate/polyphenolic extract of *Moringa oleifera* leaves for 14 days on markers of oxidative stress in mice treated with CCl₄. The authors observed that the supplementation with *Moringa oleifera* leaves extract in CCl₄-intoxicated rats prevented the increase in lipid peroxide oxidation (LPO) levels, the decrement of glutathione (GSH) concentration and in the activities of superoxide dismutase (SOD) and catalase (CAT) antioxidant enzymes in liver and kidney compared to negative control. Interestingly, the effects obtained in the group treated with 100 mg/kg bw/day of leaves extract were comparable to those obtained in the standard group treated with 50 mg/kg bw/day of vitamin E.

Sofosbuvir treatment in the present study led to congestion of blood vessels and leukocytic infiltration, which may be related to a prominent immune response of the body tissues by movement of fluids and leukocytes from the blood vessels to the intravascular tissue. This consequently causes concentration of erythrocytes leading to increase blood viscosity and slow the circulation which microscopically translated by numerous dilated small vessels packed with erythrocytes (Mitchell & Cotran, 2003)(6). In agreement with our results, Salem et al. (2017)(7) and El Gharabawy et al. (2019)(8) reported that sofo treatment induced leukocytic inflammatory cells in the connective tissue stroma and congested dilated blood vessels in different organs in rats.

Luqman et al. (2012)(9) studied the effects of administration of amounts of both aqueous and alcoholic extract of *Moringa oleifera* leaves on markers of oxidative stress in Swiss albino mice. The authors observed an enhancement of GSH concentration in mice erythrocytes treated with the aqueous extract of

Moringa oleifera leaves. The observed rise is consistent with the increase in the dose of the extract. Similarly, the dose-responsive effect on LPO was also observed. Moreover, the basal value of malondialdehyde (MDA) concentration was maintained in case of the aqueous extract of *Moringa oleifera* leaves. Milder, but appreciable, results were obtained using ethanolic extract.

Moyo et al. (2012)10)) studied the antioxidant properties of diet supplemented with *Moringa oleifera* dried leaves in goats model. The authors found a significant increment of the activity of GSH in goats supplemented with Moringa leaves as compared with the control group. In comparison, the activities of catalase (CAT) and superoxide dismutase (SOD) of diet supplemented with *Moringa oleifera* were increased appreciably than the goats fed with ordinary feed. Finally, the supplementation of *Moringa oleifera* leaves inhibited the amount of MDA generated in liver homogenate.

Conclusion

Radiation damage to renal histology causes degenerative changes and combined treatment with mercury shows synergistic effects. Moringa treatment to mice prevent oxidative damage, depicted superoxide scavenging and lipid peroxidation inhibition. A significant amount of increase in GSH concentration was also discussed. In conclusion Moringa may be used for developing novel radioprotective drug.

References

1. B. Moyo, S. Oyedemi, P.J. Masika, V. Muchenje (2012). Polyphenolic content and antioxidant properties of Moringa oleifera leaf extracts and enzymatic activity of liver from goats supplemented with Moringa oleifera Leaves/sunflower seed cake. *Meat Sci.*, 91, 441–447.
2. El. Gharabawy, G.S.H., Abdallah, E.E.A., Kaabo, H.F., & Abdel Aleem, A.M.A. (2019). Histological effects of sofosbuvir on the kidney of male albino rats and the possible protective role of vitamin C. *The Egyptian Journal of Hospital Medicine*, 76(1), 3335–3354.
3. J.V. Corbett (2008). *Laboratory tests and diagnostic procedures with nursing diagnoses*. 7th Ed., pp. 90–107.
4. R.N. Mitchell, & R.S. Cotran (2003). Acute and chronic inflammation. In Kumar, V., Cotran, R.S., & Robbins D.S.L. (7th Ed), *Robbins Basic Pathology* (p. 35). Philadelphia, Elsevier Saunders.
5. S. Luqman, S. Srivastava, R. Kumar, A.K Maurya, D. Chanda (2012). Experimental assessment of Moringa oleifera leaf and fruit for its antistress, antioxidant, and scavenging potential using in vitro and in vivo assays. *Evid. Based Complement. Alternate. Med.* <https://doi.org/10.1155/2012/519084>
6. S.S Pracheta, V. Sharma, R. Pallial, S. Sharma, L. Singh, B.S. Janmeda, S. Yadav, & S.H. Sharma (2011). Chemoprotective activity of hydro-ethanolic extract of Euphorbia neriiifolia Linn leaves against DENA-induced liver carcinogenesis in mice. *Biology and Medicine*, 3(2), 36–44.
7. S. Sreelatha, P.R Padma (2009). Antioxidant activity and total phenolic content of Moringa oleifera leaves in two stages of maturity. *Plant Foods Hum. Nutr.*, 64, 303–311.
8. Z.A. Salem, D.A. Elbaz, & D.B. Farag (2017). Effect of an anti-hepatitis C viral drug on rat submandibular salivary gland. *Egyptian Dental Journal*, 63(1), 657–665.
9. Z.F. Ma, J. Ahmad, H. Zhang, I. Khan, & S. Muhammad (2020). Evaluation of phytochemical and medicinal properties of moringa (*Moringa oleifera*) as a potential functional food. *South African Journal of Botany*, 129, 40–46.