

A Case Report on Cervicofacial / Cervicothoracic Rotation Flaps in Head and Neck Surgery

Neeraj Kumar¹, Rajarshi Banerjee², Subhransu Basu³,
Abhinaba Bose⁴, Sudipta Sahu⁵.

¹PGT, DEPT. OF ORAL & MAXILLOFACIAL SURGERY, HALDIA INSTITUTE OF DENTAL SCIENCES & RESEARCH.

²HOD & PROFESSOR, DEPT. OF ORAL & MAXILLOFACIAL SURGERY, HALDIA INSTITUTE OF DENTAL SCIENCES & RESEARCH.

³PROFESSOR, DEPT. OF ORAL & MAXILLOFACIAL SURGERY, HALDIA INSTITUTE OF DENTAL SCIENCES & RESEARCH.

^{4,5}ASSOC. PROFESOR, DEPT. OF ORAL & MAXILLOFACIAL SURGERY, HALDIA INSTITUTE OF DENTAL SCIENCES & RESEARCH.

Abstract

Introduction: The large defects resulting from head and neck tumour surgeries present a reconstructive challenge to surgeons. Although numerous methods can be used, they all have their own limitations. In this paper, we present our experience with cervicofacial/cervicothoracic rotation flaps to help expand the awareness and application of this flap.

Case report: of a patient who underwent repair of defects of the head and neck with cervicofacial/cervicothoracic flap in our department has been presented and clinical factors were recorded.

Discussion: Cheek neoplasms are the most common indication for cervicofacial/cervicothoracic rotation flaps, followed by parotid tumours. Defects measuring 6 cm × 7 cm × 1 cm were reconstructed by cervicothoracic flap in this case with acceptable result.

Conclusions: Cervicofacial/cervicothoracic flaps provide a technically simple, reliable, safe, efficient and cosmetic means to reconstruct defects of the head and neck.

Keywords: Flaps, Cervicothoracic, Head and Neck surgery.

1. INTRODUCTION

In recent years, with the advancement of microsurgical methods, new flap techniques offer great hope for the future of head and neck reconstruction, that include radial forearm free flap, anterolateral thigh free flaps [1], rectus abdominis myocutaneous flap [2], and latissimus dorsi flap [3]. However, to optimise the cosmetic and functional outcomes for any given individual surgical wound, the head and neck surgeon must possess a firm grasp of fundamental techniques as well as the ability to use a reconstructive modality that meets the unique demands of each defect, as ascertained through multiple meta-analysis [4].

Though free tissue transfer is a good option for reconstructing defects but it has a certain limitations as well. The proper reconstruction method shall be chosen by the surgeon keeping in mind the following factors a) patient's general body status b) the match of the texture and colour of the flap with the recipient

region c) the anatomic location d) medical comorbidities e) whether two operation sites are needed f) and the surgeon's clinical expertise and preference .

The pedicle flap can include random pattern flaps and axial pattern flaps. A random blood supply pattern is needed to maintain a wide pedicle [5]. Therefore, many random flaps, such as cheek advancement-rotation flaps and forehead flaps, have poor mobility and are only suitable for reconstructing small defects. Although axial flaps (e.g., trapezius flaps [6] and pectoralis major myocutaneous flaps (PMMF) [7] can overcome these limitations, they often appear too bulky or large, resulting in a poor colour and texture match with the recipient site, and sometimes impair the function of the donor muscle group.

First described by Esser in 1918, the cervicofacial flap was first described in its modern form by Juri and Juri in 1979[1]. It is a random pattern flap comprising skin, subcutaneous fat, superficial neck veins, and platysma muscle. It includes the delicate superficial cervical fascia just deep to skin that envelopes the platysma and muscles of facial expression and extends from the epicranium above to the axilla and upper chest below; over the face it is represented by the superficial musculo-aponeurotic system (SMAS).[8]

The cervicofacial flap has a wide pedicle and can be employed to cover large anterolateral craniofacial defects. Superiorly it can reach the supraorbital margin, laterally the postauricular area and medially up to the midline.[9]

The cervicofacial flap provides a) an excellent colour match as well as thickness and texture b) can be performed under local anaesthesia c) provides concomitant exposure for neck dissection and parotidectomy d) has very acceptable donor site scars e) scars are camouflaged in the cheek borders f) requires minimal surgical time g) minimal postoperative morbidity.[10]

As it is a thin flap, additional bulk may be provided with a pectoralis major muscle flap placed deep to the cervicofacial flap.[11] It may also be an option for patients not suitable for free tissue transfer e.g elderly or medically compromised patients who cannot tolerate prolonged surgical time.[12]

1.1 Arterial supply

The blood supply of the cervicofacial flap can be divided into 2 portions i.e. facial and cervical. The facial portion of the flap receives its blood supply via the subdermal plexus in a random pattern from the facial artery, transverse facial artery and the superficial temporal artery via its orbito-zygomatic branch. It is dissected in a subcutaneous plane. A modification of this portion of the flap technique is to incorporate the SMAS as proposed by Kroll [13] to enhance the vascularity by providing the flap with an axial blood supply via perforators from the transverse facial artery.

The cervical portion of the flap, on the other hand, is dissected in a subplatysmal plane. By doing so, the platysma provides blood supply to this region. The platysma, as described by Hurwitz [14] , is supplied by the occipital and postauricular arteries posteriorly, the submental artery superiorly and medially, the superior thyroid artery centrally and the transverse cervical artery inferiorly (Figure 1). However, during flap elevation, only the perforators from the submental artery are preserved.

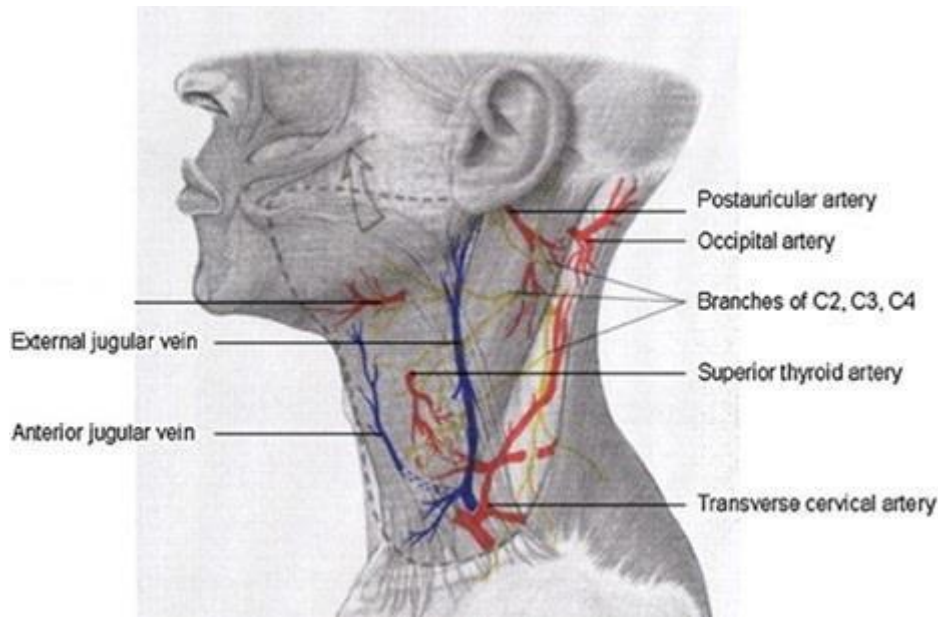


Figure - 1

1.2 Venous drainage

Both the facial and cervical portions have a venous system that accompanies the arteries. The venous drainage is however mainly provided by the external jugular vein and randomised dermal venous drainage (Figure 1). Enclosing the external jugular vein in the flap helps to reduce venous congestion and the risk of ischaemic necrosis.

1.3 Innervation

Sensory innervation is provided by branches of the greater auricular (C2-C3) and lesser occipital (C2) nerves. Careful dissection reduces the risk of paraesthesia and patients should be informed of this potential complication prior to the surgery.

2. Case report

A 65 year old female patient with an ulcerative lesion in preauricular region of right side of face and with a myriad of comorbidities, including hypertension, diabetes mellitus, was reconstructed with cervicofacial rotation flap. Histologic diagnosis was squamous cell cancer. The size of the defects was 6 cm × 7 cm × 1 cm. cTNM-T_{4a}N₁M_x.

The incision begins from the posterolateral aspect of the resection margins. By carrying the incision below the lobule and then up to the mastoid tip, it can then be dropped into the neck along the anterior edge of the trapezius muscle, the lateral third of the clavicle, and extending into the pectoral region. (Figure 2) The incisions include potential avenues for a back cut along natural skin creases. If the base of the inferior limit of the incision is up to the clavicle, the flap is named a cervicofacial flap. If the base of the inferior limit is down to the clavicle, then the flap is named a cervicothoracic flap.

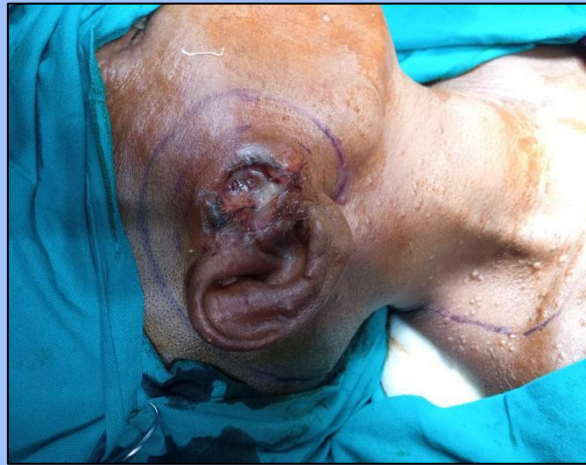

Figure - 2

The flaps was raised superficial to the superficial musculoaponeurotic system (SMAS) and the parotidomasseteric fascia, deep to the platysma, (Figure 3,4) and then transferred into the outer skin defect and sutured.(Figure 5,6) without tension.

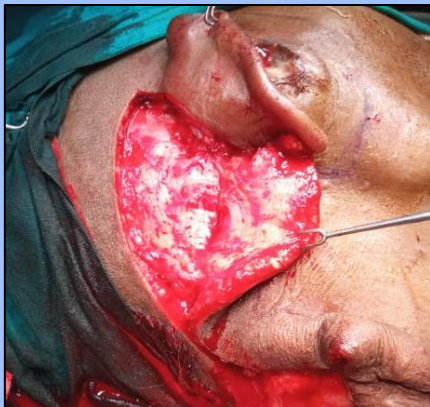

Figure - 3

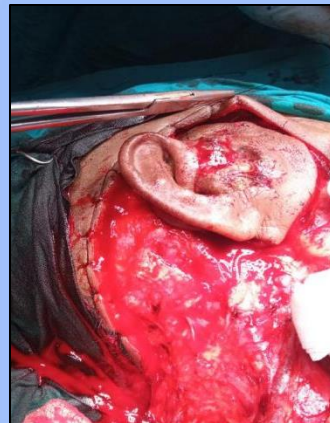

Figure - 4

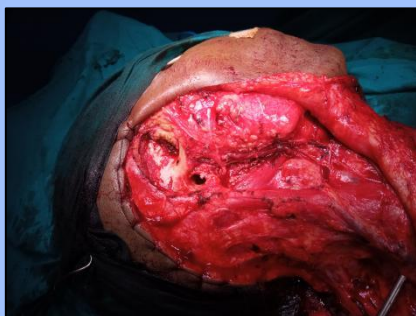


Figure- 5

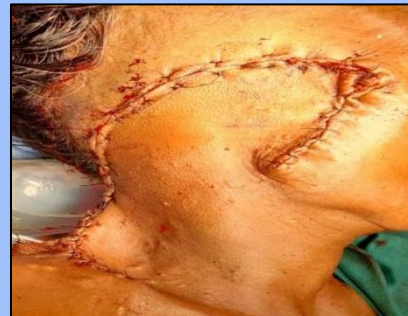

Figure - 6

3. Discussion

Large defects of the head and neck present a significant reconstructive challenge to surgeons, especially when simultaneous parotidectomy and neck dissection is required.

The rotation of locoregional tissue remains a mainstay of reconstruction in these anatomic regions. Cervicothoracic flap provides an excellent skin colour and texture match, requires no donor region, reduces the surgical risk to high-risk patients, such as those with complications of hypertension, diabetes, or old age. The random flap is widely used to repair small defects of the head and neck.

In addition to providing an excellent skin colour, texture and thickness match, the tissue is flexible, minimise distortion of the eye and upper lip were noted, facial movement was preserved and ectropion was avoided[15]. The cervicofacial/cervicothoracic flaps meet all of these criteria.

In a sense, they are the simplest method of providing soft tissue coverage for the protection of deeper vital structures, such as the facial nerve, mandible and carotid. The upper boundary of reconstruction with this method can reach to the supraorbital margin, the medial boundary can reach to the median line and the outer boundary can reach to the pre-auricular or post-auricular region.

In general, complication manifested as distal tip necrosis and epidermolysis of the distal skin flap. Full thickness flap necrosis being rare.

This flap is primarily useful in relatively superficial defects because they are too thin to provide the necessary bulk of tissue for deeper repairs.

3.1. Methods of lowering complications

- a) Carefully protect the superficial cervical fascia surrounding the platysma and thus preserve the capillary network in the fascia.
- b) During the flap harvest, elevate the superficial veins with the flap, even though they are ligated on both sides. Residual vein can be helpful in re-establishing blood circulation.
- c) when resecting the tumours, take care not to produce excessive thinning of the skin surrounding the defect. Thus, the distal aspect of the flap can be provided with more subcutaneous tissue, which could supply a rich network of subdermal anastomoses.

4. Conclusion

Because cervicofacial/cervicothoracic flap techniques are anatomically sound, technically simple, reliable and safe, they are useful methods for the reconstruction of surgical defects of the head and neck and will more frequently attract the attention of surgeons in the future.

5. Conflict of Interest

There is no conflict of interest with anybody/any organization and no sponsors were obtained.

6. REFERENCES

1. Wong CH, Wei FC: Microsurgical free flap in head and neck reconstruction. *Head Neck* 2009.
2. Schliephake H, Schmelzeisen R, Neukam FW: The free revascularized rectus abdominis myocutaneous flap for the repair of tumour related defects in the head and neck area. *Br J Oral Maxillofac Surg* 1996, 34:1-22.
3. Valentini V, Gennaro P, Torroni A, Longo G, Aboh IV, Cassoni A, Battisti A, Anelli A: Scapula free flap for complex maxillofacial reconstruction. *J Craniofac Surg* 2009, 20:1125-1131.
4. Moore BA, Wine T, Netterville JL: Cervicofacial and cervicothoracic rotation flaps in head and neck reconstruction. *Head Neck* 2005, 27:1092-1101.
5. Tan ST, MacKinnon CA: Deep plane cervicofacial flap: a useful and versatile technique in head and neck surgery. *Head Neck* 2006, 28:46-55.
6. Guillaumondegui OM, Campbell BH: The folded trapezius flap for through-and-through cheek defects. *Otolaryngol Head Neck Surg* 1987, 97:24-27.
7. Ahmad QG, Navadgi S, Agarwal R, Kanhere H, Shetty KP, Prasad R: Bipaddle pectoralis major myocutaneous flap in reconstructing full thickness defects of cheek: a review of 47 cases. *J Plast Reconstr Aesthet Surg* 2006, 59:166-173
8. Juri J, Juri C. Advancement and rotation of a large cervicofacial flap for cheek repairs. *Plast Reconstr Surg* 1979; 5:692-6 .
9. Mitz V, Peyronie M. *Plastic & Reconstructive Surgery* 1976. 58(1):80
10. Schaverien MV, Pessa JF, Saint-Cyr M, *et al.* The arterial and venous anatomies of the lateral face lift flap and the SMAS *Plast Reconstr Surg.* 2009; 123(5): 1581-7
11. Hakim SG, Jacobsen HC, Aschoff HH. *et al.* Including the platysma muscle in a cervicofacial skin rotation flap to enhance blood supply for reconstruction of vast orbital and cheek defects: anatomical considerations and surgical technique *Int J Oral Maxillofac Surg.* 2009;38(12):1316-9
12. Roth DA, Longaker MT, Zide BM. Cheek surface reconstruction: best choices according to zones *Operat Tech Plast Reconstr Surg.* 1998;5(1):26-36
13. Close SS, Kroll GP, Reece G. *et al.* Deep-plane cervicofacial rotation advancement flap for reconstruction of large cheek defects *Plast Reconstr Surg.* 1994;94(1):88-93
14. Close DJ, Hurwitz JA, Rabson JW, Futrell JW. The anatomic basis for the platysma skin flap. *Plast Reconstr Surg.* 1983;72(3): 302-121414
15. Cook TA, Israel JM, Wang TD, Murakami CS, Brownrigg PJ: Cervical rotation flaps for midface resurfacing. *Arch Otolaryngol Head Neck Surg* 1991, 117:77-82.