

Paranasal Sinus Infection Leading to Orbital Compartment Syndrome – A Case Report.

Megalah Selvamani¹, Prof Dr. Prepageran Narayanan²

¹Doctor, Department of Otorhinolaryngology, University Malaya Medical Centre.

²Professor, Department of Otorhinolaryngology, University Malaya Medical Centre.

Abstract:

Sinusitis is the inflammation of the paranasal sinus. Symptoms vary; it includes nasal obstruction, purulent discharge from the nose, facial pain, headache mainly in the frontal region, fever, hyposmia, and generalized malaise. Infection can be caused by a virus, which is the most common, followed by bacteria and fungi. Treatment will be based on etiology and can vary between 2 to 4 weeks. Early detection of infection and initiation of treatment is crucial and can prevent complications. Orbital complication is the most common complication due to its proximity, and if it is not identified early and addressed accordingly, the outcome will be unfavorable.

Introduction:

Paranasal sinus infection is quite common and can be managed as an outpatient typically. Delayed diagnosis due to various reasons can lead to multiple life-threatening complications. Orbital complications are the most common complication of acute sinusitis, accounting for 80% of all complications. This is due to its close anatomical proximity to the paranasal sinuses. If orbital complications are not treated in time, they can progress to life-threatening complications and can even lead to intracranial infection, which is more deadly.

Central retina artery occlusion (CRAO) typically presents as sudden unilateral vision loss and is more common in men in their 50s and 60s. The prognosis for treatment after the acute phase is generally unfavourable. Vision loss is caused by vessel occlusion leading to ischemic injury affecting nerve cells that line the retina. Central retina artery occlusion is often associated with vascular thrombotic events.

We want to report a case of paranasal sinus infection leading to orbital compartment syndrome, which was managed urgently with bedside canthotomy and cantholysis.

Case Report

A 63 years old Chinese gentleman presented with a right-sided nasal block with mucopurulent discharge for five days. On day 3 of illness, he developed swelling over his right cheek, which extended to the right periorbital region. He complained of blurring of right eye vision, which worsens progressively. He also had pain over his facial region, especially over the maxillary and frontal, which was not tolerable with given oral analgesics. His oral intake was reduced due to the pain. He denies any toothache and does not have any ear or throat concerns. There was no history of neck swelling. He was diagnosed with left renal cell carcinoma and underwent a left nephrectomy in 2016. Five years ago, he also underwent functional endoscopic sinus surgery for chronic rhinosinusitis with a nasal polyp.

On examination, he is a moderately built man. Hydration was fair. External examination of the nose was unremarkable. Anterior rhinoscopy showed mucopurulent discharge in the right nasal cavity. The cold spatula test showed reduced misting over the right side. Nasal endoscopic examination over the right nostril revealed evidence of previous nasal surgery, mucopurulent discharge from the right osteo-meatal complex, and also a small polyp over the anterior ethmoid region (Image 1a and 1b). Endoscopic examination over the left nostril was unremarkable. There was right eye ptosis with ophthalmoplegia. (Image 2) .Intraocular pressure was measured and was within normal range. Visual acuity over the right eye was 6/36. There was no cervical lymphadenopathy. Other ears, nose, and throat examination was unremarkable.

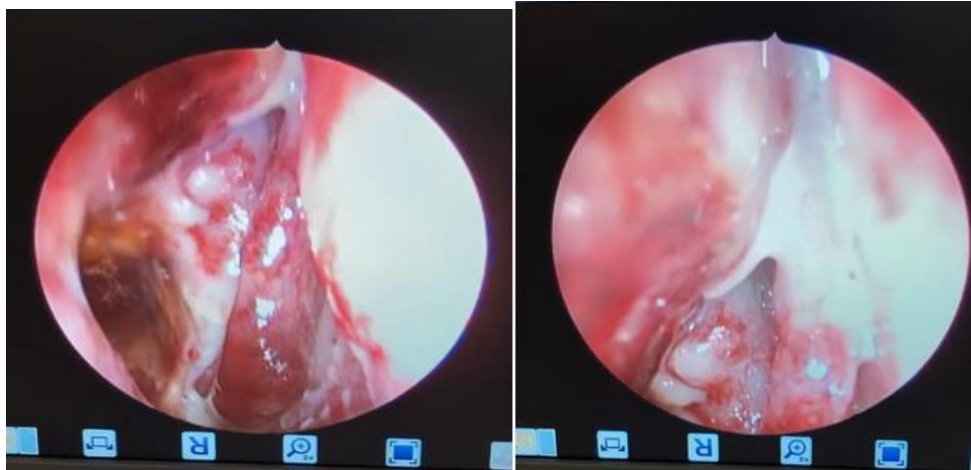


Image 1a

Image 1b

Image 1a shows an inflamed, sloughy, and blood-stained right nasal cavity. There is evidence of middle meatal antrostomy with crusting and pus discharge.

Image 1b shows slough and mucopurulent over the middle turbinate.

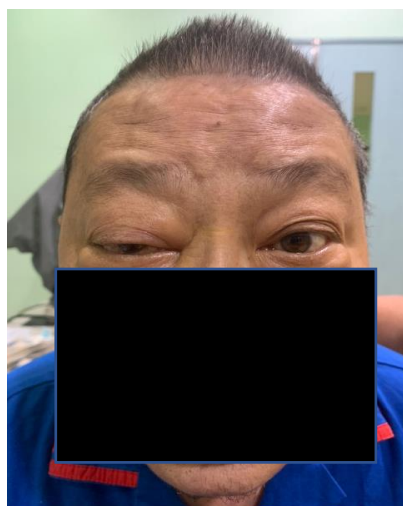

Image 2 - shows right eye ptosis with ophthalmoplegia.

Contrast-enhanced Computer Tomography of the paranasal sinuses and orbit showed mucosal thickening in the right maxillary and ethmoid sinuses with minimal enhancing septation within. There was cutaneous and subcutaneous thickening with fat stranding overlying right maxillary sinus, extending across the orbital septum with pre and post-septal involvement. Mild thickening of the right inferior, medial, and lateral rectus muscles was also seen. However, there was no evidence of rim-enhancing intra-orbital collection. (Image 3a,3b,3c,3d)

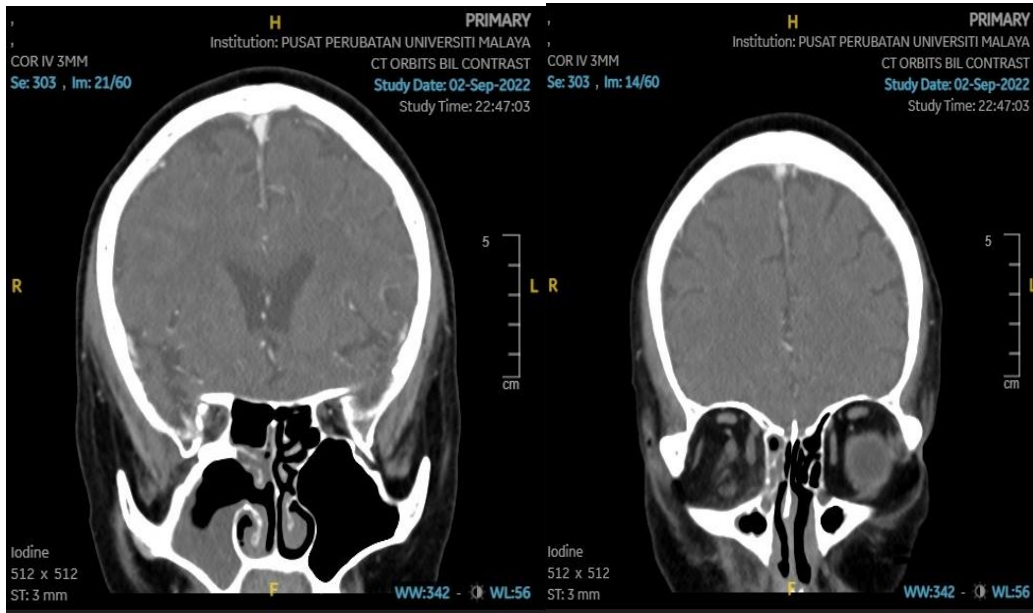


Image 3a

Image 3b

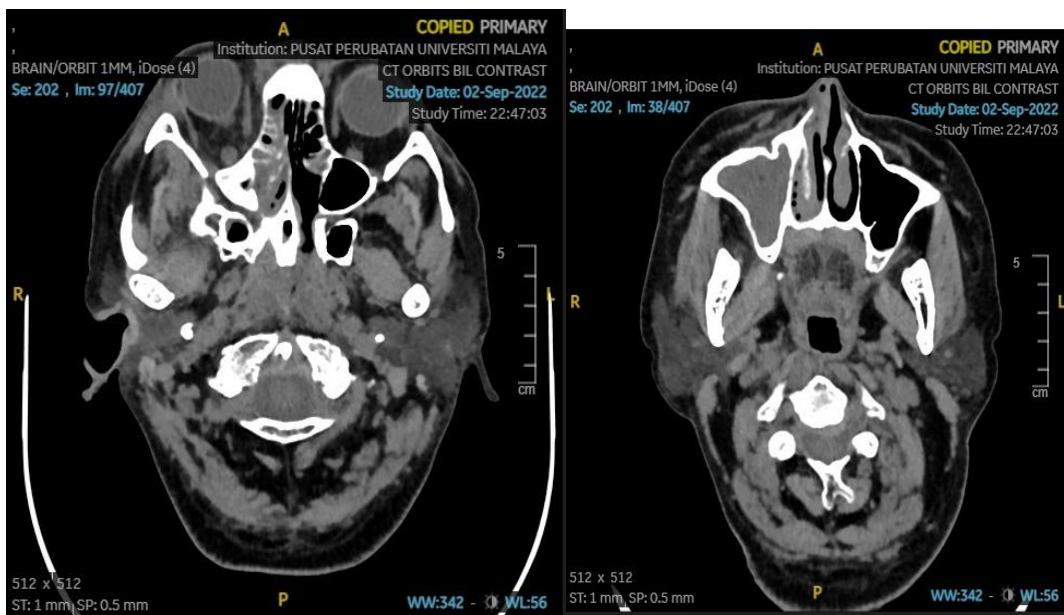


Image 3c

Image 3d

The patient was admitted and started on broad-spectrum antibiotics. Adequate analgesics and hydration were initiated as well. The patient condition worsens several hours after admission. He complains of severe throbbing headache, especially over the frontal region, and tightness over the right eye, which worsen progressively. Clinical examination revealed loss of right eye perception to light and a sudden increase in intraocular pressure. The ophthalmology team reviewed the patient, and a right orbital compartment syndrome diagnosis was established. Bedside emergency right eye lateral canthotomy and cantholysis were performed. Post-procedure right eye globe was less tense, headache improved, and intraocular pressure reduced from 36mmhg to 15mmhg. However, after re-examining the right eye, there was still no perception of light.

The patient's general condition and vision did not improve despite the emergency canthotomy and cantholysis procedure. The patient and family members opted for conservative intervention. He deteriorated further and succumbed despite all the medical treatment given.

Discussion.

The incidence of complications due to acute sinusitis has declined tremendously due to early detection and treatment. Patients' awareness of their medical condition also plays a significant role. The usage of wide-spectrum antibiotics and early treatment initiation also contributed to this. Orbital complications are more frequent because of the close anatomical relationship between the orbital content and the paranasal sinuses. Multiple blood vessels traversing through the lamina papyracea help spread infections from the paranasal sinuses to the orbit. Orbital compartment syndrome is an emergency that leads to vision-threatening elevation of intra-orbital pressure that exceeds the ophthalmic artery's vascular perfusion pressure. It can result in ischemia and irreversible vision loss if not corrected emergently. Emergency bedside canthotomy and cantholysis procedures are crucial to save patients' vision.

Conclusion.

A thorough patient history and clinical examination are essential in suspected acute sinusitis. Medical treatment is always the first treatment offered to patients with complicated sinusitis, irrespective of the site and the severity. Emergency bedside procedures can be lifesaving, especially involving orbital complications. Identifying acute orbital complications is crucial because a slight delay can lead to permanent vision loss. Attending to the patient's complaint can aid in the early identification of acute complications. Surgery is indicated whenever the condition does not respond to conservative management.

Reference.

1. Intraorbital and Intracranial Complications of Acute Rhinosinusitis: A Rare Case Report. Iran J Otorhinolaryngol. 2018 Sep; 30(100): 301–304.
2. https://eyewiki.org/Orbital_Compartment_Syndrome
3. International Journal of Emergency Medicine. Orbital compartment syndrome from retrobulbar hemorrhage. <https://intjem.biomedcentral.com/articles/10.1007/s12245-010-0245>.
4. Orbital Compartment Syndrome: An Update With Review Of The Literature. <https://www.dovepress.com/orbital-compartment-syndrome-an-update-with-review-of-the-literature-peer-reviewed-fulltext-article-OPHTH>