

Retained Deciduous Teeth in Indore, Madhya Pradesh: A Retrospective Study

Dr. Neelesh Gautam¹, Dr. Updesh Masih², Dr. Akshada Chougankar³

¹3rd year Post-Graduation, Pediatric and Preventive Dentistry, Sri Aurobindo College of Dentistry

²Professor and Head, Pediatric and Preventive Dentistry, Sri Aurobindo College of Dentistry

³2nd year Post-Graduation, Pediatric and Preventive Dentistry, Sri Aurobindo College of Dentistry

Abstract-

Retention of primary teeth beyond the expected time of exfoliation is uncommon; this condition is known as persistence. A retained primary tooth, with the crown in good condition, roots, and supporting alveolar bone can serve adults for many years.

Aims-

To determine the prevalence of retained primary teeth and investigate the consequences of their persistence.

Materials and Methods- ORTHOPANTAMOGRAM (OPG) data obtained from pediatric and preventive dentistry of 500 patients, were investigated and examined for the presence of retained primary teeth.

Result-

The total occurrence of retained primary teeth was 64 out of a sample of 500. The Occurrence of Ankylosed teeth, ectopic eruption, agenesis, Impaction being 0, 15, 48, 1 respectively. The prevalence of retained primary teeth in the selected population is 12.8%. The prevalence of Ankylosed teeth, ectopic eruption, agenesis, Impaction is 0%, 3%, 8.6%, 0.2% and respectively.

Conclusion-

We found that primary teeth were retained in 12.8% of the study population. The most frequent causes of primary molar retention were agenesis of the permanent successor, followed by ectopic eruption and impaction of the successor teeth.

Keywords- Agensis, Ectopic Eruption, Impaction, Ankylosis.

Introduction

The retention of primary teeth beyond their expected time of exfoliation is an uncommon condition, known as persistence or retention. Only a limited number of reports have investigated the persistence of primary teeth. [1-3]

Retention of primary teeth can result in several complications, which require orthodontic treatment or surgical intervention.

Ankylosis of the primary teeth leave the primary teeth submerged or in a significantly infra-occlusion position. With such loss of arch integrity, tipping of the adjacent permanent teeth usually occurs and complicates proper alignment of the dentition. Ankylosis of the primary teeth could occur in addition to ectopic eruption or after impaction of permanent teeth. This leads to a localized or generalized loss of the required arch length and would eventually result in malocclusion and crowding of the dentition. [4]

The most common reason was the developmental absence of a permanent successor tooth or congenitally missing permanent premolars. Mandibular second premolars appear to be the most frequent congenitally missing successors. Teeth agenesis was more common in females, with a female: male ratio of 1.37:1. [5-6]

Teeth agenesis was a dental malformation that was one of the most common congenital malformations in humans. Children with agenesis of multiple permanent successor tooth germs were expected to develop persistence of primary teeth more frequently than those without agenesis of the permanent teeth. A cross-sectional study found that the most commonly retained predecessor was the mandibular second primary molar teeth, followed by the maxillary deciduous canine. [7]

In a study conducted by Aktan et al. in 2011, primary teeth were more frequently retained in the mandible than in the maxilla, and the right side was less affected than the left side. [8] However, previous studies have not clearly explained the reasons for the retention of primary teeth.

Methods

Records of the patient who reported in Sri Aurobindo college of dentistry, Indore, Madhya Pradesh in the department of Pediatric and Preventive Dentistry were collected and evaluated.

Extra-oral panoramic radiographs of the included patients were examined.

In the radiographic examination, the reasons for the persistence of the primary teeth as well as the characteristics of the retained primary teeth was being evaluated.

In addition, we determined whether the teeth showed evidence of having pathological conditions, such as periodontal problems, ankylosis, infra-occlusion, cystic lesion, and tipping of the adjacent permanent teeth.

Tooth agenesis was determined from panoramic radiographs by screening for the absence of permanent tooth germ.

Ankylosis of primary teeth was determined when complete cohesion was noticed between the roots and the invested bony structure.

An ectopic path of eruption of the permanent successor was being observed on the panoramic radiograph when the long axis of the erupting tooth formed an angle other than 90° with its overlying predecessor.

The presence of infra-occlusion of deciduous teeth can be detected when vertical discrepancy exceeding 3 mm, as measured from the mesial marginal ridge of the permanent teeth.

Using these definitions, the proportions (in percentage) of cases demonstrating these features were determined.

Results

The total occurrence of retained primary teeth was 64 out of the sample of 500.

The Occurrence of Ankylosed teeth 0%, Ectopic Eruption 15%, Agenesis 48%, Impaction 1% respectively. The prevalence of retained primary teeth in the selected population was 12.8%.

The prevalence of ankylosed teeth, ectopic eruption, agenesis, impaction and is 0%, 3%, 8.6%, 0.2% and respectively.

Table.1 Percentage distribution of retained primary between the sexes.

Group (64)	Retained Primary Teeth	Incisor	Canine	Molar
Male (32)	24%	8	7	9
Female (32)	24%	7	8	9

Table. 2 Causes of primary teeth retention.

Groups	Prevalence Rate
Agenesis	8.6%
Ectopic Eruption	3%
Impaction	0.2%
Ankylosis	0%

Statistical Analysis

Descriptive statistics were used to find the frequencies, mean, standard deviation of variables considered in the study. The level of significance was set at 5% that is the p-value of <0.05% was being considered to be statistically significant.

The Chi-square test was used to compare the frequency of retained primary teeth among the sexes.

Discussion

Dental infraocclusion is defined as teeth below the occlusal plane. In the literature, the terms submergence and infraocclusion are often used to refer to an ankylosis.

The frequency of ankylosed teeth has been reported to be between 1.3% and 38.5%. The mandibular first primary molars are the most frequently affected teeth, followed by second mandibular and maxillary primary molars.

The exact cause of teeth ankylosis is still unknown, but several theories have been proposed such as familial pattern, traumatic injury to Hertwig’s epithelial root sheath, deficiency in bone growth, a problem in local metabolism and inflammation, localized infection, and chemical or thermal irritations.

Ankylosis is classified as slight, moderate, or severe according to the place of the occlusal level of the infraoccluded tooth

Bloch-Jorgensen was the first to report severe cases of “retained deciduous teeth” in one of the first radiographic studies of infraocclusion.

Winter et al. reported on 28 cases with severe infraocclusion, including failure of eruption, and Quintero et al. evaluated the treatment outcome of severe infraocclusion cases, recommending early treatment.

Tooth eruption is a process whereby the forming tooth migrates from its intraosseous location in the jaw to its functional position within the oral cavity. A variety of eruption problems arise during the transitional dentition period and one such problem is ectopic eruption.

Nikiforuk who also classified ectopic eruptions, defined them as “a condition in which the permanent teeth, because of deficiency of growth in the jaw or segment of jaw, assume a path of eruption that

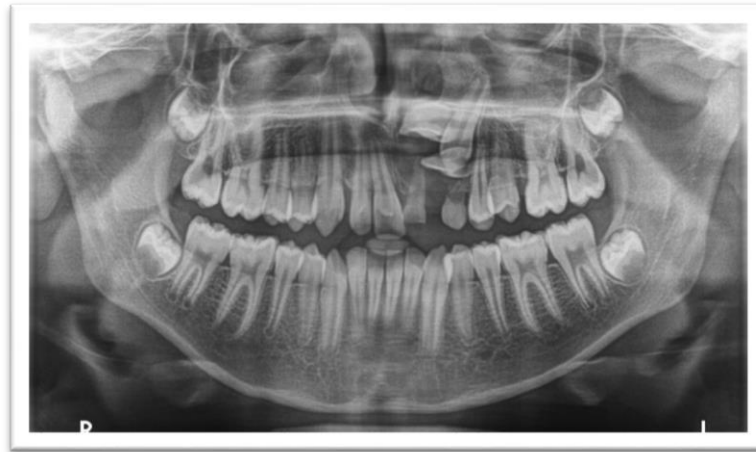intercepts a primary tooth, causes its premature loss and produces a consequent malposition of the permanent tooth. [9]

One of the earliest reports on ectopic eruption was by Chapman who, in 1923, described four cases of ectopic eruption of the maxillary first permanent molars in which he listed four possible causes:

- Small arches,
- Deviant paths of eruption of the permanent molar,
- Lack of forward movement of all primary teeth, and
- Early eruption of the maxillary first permanent molars.

The etiology of ectopic eruption can, therefore, be summarized as being a disturbance of the differential growth pattern of the individual. Different tissues and organs grow at different rates and at different times. A delicate balance normally exists between the timing and rate of growth. Differential growth is the basis for normal and harmonious completion of various physiologic processes including the eruption of teeth.

Figure.1- Ectopic Eruption



Tooth agenesis is a very common developmental dental anomaly of human dentition, and the most common dental anomaly among different ethnic groups, with third molars being the most common missing tooth.

Tooth agenesis, based on the number of missing teeth, commonly termed hypodontia, is characterized by the congenital missing of one to five teeth, excluding the third molars. Oligodontia refers to congenital missing of six or more teeth, excluding third molars, and anodontia represents total missing of teeth in the dental arches which is extremely rare.

Congenital absence of teeth or Hypodontia is one of the most common abnormalities in tooth development in human beings. The prevalence of hypodontia varies from 2.63% to 11.2%, depending on the race.

The most frequently missing permanent teeth according to rank are the maxillary lateral incisors, second premolars and third molars, while missing maxillary central incisors, canines and first molars are very rare. Hypodontia can be classified as non-syndromic or sporadic when the absence of a tooth is an isolated anomaly, or syndromic when it is a part of a complex of multiple congenital anomalies.

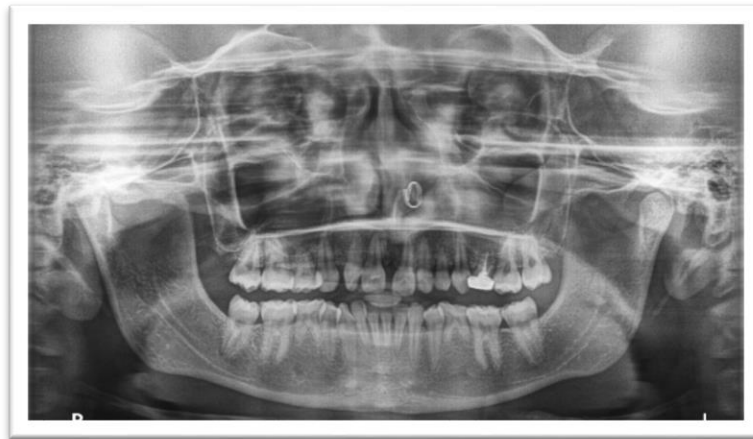
Etiological factors related to tooth agenesis can be environmental or genetic resulting in failure of tooth development. Heredity is the main factor for missing teeth due to an autosomal dominant gene with incomplete penetrance.

It can also be a result of systemic factors such as endocrine disturbances, a part of a syndrome or due to environmental factors such as radiation or facial trauma.

In patients with congenitally missing teeth, deformities in tooth size and shape (peg shaped or small laterals) are more frequent. Peg-shaped lateral incisors can be considered as an incomplete expression of the gene responsible for agenesis of this tooth. The high prevalence of tooth agenesis and peg-shaped lateral incisors suggests a common genetic etiology.

previous studies on the incidence of missing permanent teeth reported varied conclusions based on ethnic differences. For example, characteristic to Asian ethnicity, the mandibular second premolars and mandibular incisors are the most frequently missing teeth while in a Caucasian population the mandibular second premolars and the maxillary lateral incisors are reported as most likely to be missing.

Figure.2- Tooth Agenesis



Hoffmeister (1977) and Pfeiffer (1974) suggested that developmental anomalies such as hypodontia, supernumerary teeth, peg-shaped lateral incisors, and ectopic eruption of maxillary first permanent molars are all micro symptoms of a hereditary disturbance due to a general disturbance of the tooth developmental structures.

Rune and Sarnäs (1984) found no correlation with dental decay or submergence and no relationship between any particular root resorption stage and submergence.

Agenesis of the permanent second premolars was found to be the most common reason for the retention of the primary molar, followed by ectopic eruption of the permanent successor and impaction of the permanent successor.

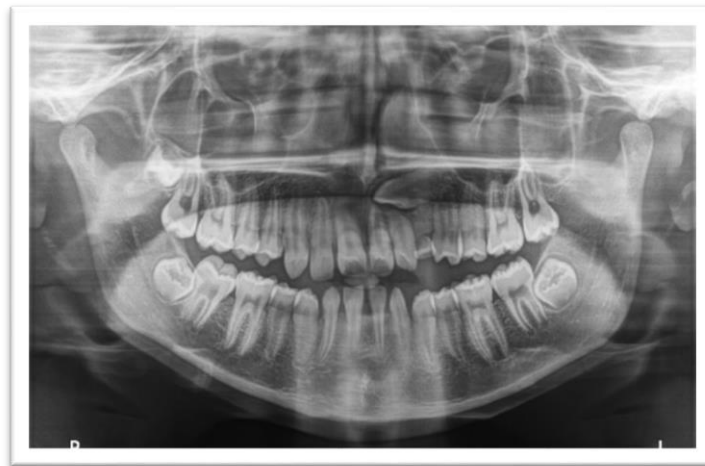Impacted teeth are those with a delayed eruption time or that are not expected to erupt completely based on clinical and radiographic assessment.

These factors may include mechanical obstruction (by a supernumerary tooth, cyst, or tumor); insufficient space in the dental arch due to skeletal incongruities (micrognathia); or to the premature loss of deciduous teeth or a tooth arch size discrepancy. Systemic factors such as genetic disorders, endocrine deficiencies, and previous irradiation of the jaws are also associated with a failure of tooth eruption. In systemic conditions multiple teeth are usually impacted. In most cases, however, the specific cause of failure of eruption remains unknown.

All teeth can be impacted; however, third molars, maxillary canines, maxillary and mandibular premolars, and maxillary central incisors are the teeth most frequently involved. The prevalence of impacted maxillary canines is 0.9–2.2%, but mandibular canine impaction occurs less frequently.

Mandibular canine impaction is regarded as a much rarer phenomenon, and there are limited numbers of studies revealing its frequency of occurrence. Grover and Lorton found only impacted canines (0.22%) in the mandible in 5000 individuals. Chu et al. reported five mandibular impacted canine (0.07%) teeth in 7486 patients. A study by Rohrer examining 3,000 patients radiographically found 62 impacted maxillary canines (2.06%) and only three impacted mandibular canines (0.1%), a 20:1 ratio. In another study by Aydin et al. involving 4500 Turkish patients, the incidence of mandibular canine impaction was 0.44%. The ratio in the present study (1.29%) has been found higher than the published literature to date. Definitely, maxillary canine impaction is more frequent than is mandibular canine impaction.

Figure.3- Impacted Canine



The prevalence of retained primary deciduous in 6–20 years old children of the Indore area. In this study, agenesis of the permanent second premolars was found to be the most common reason for the retention of the primary molar, followed by ectopic eruption of the permanent successor and impaction of the permanent successor.

The prevalence of retained primary deciduous reported in our study (12.8 %) was relatively higher as compared to the data available from other Indian studies. The prevalence of retained primary deciduous was found to be 9.4% in Udaipur, 9.2% in Gujarat, 8.9 % in Karnataka and 6.31% in Chandigarh.

Retention of the primary mandibular second molars is most often due to agenesis of the permanent mandibular second premolars, which are their successors, followed by ectopic eruption of the permanent mandibular second premolars, and impaction of the permanent mandibular second premolars.

In cases with agenesis of permanent mandibular second premolars, preservation of the primary molars helps to maintain the bone volume and reduce bone resorption, which will later facilitate placement of an immediate implant in patients around the age of 16 years.

Retained primary molars must be carefully assessed so that all possible treatment options can be considered. If the permanent premolars were missing, preserving primary molars with or without modification is the most desirable option.

The radiographic image must be carefully examined in such cases to detect submerged primary molars i.e. ankylosis or other associated problems, such as caries in the primary molars, resorption of the primary molars, periodontal problems and bone resorption, mesial tipping of the distal or mesial permanent tooth, and supra-eruption of the opposing permanent tooth.

Conclusion

We found that primary teeth were retained in 12.8% of the study population. The most frequent causes of primary molar retention were of agenesis of the permanent successor, followed by ectopic eruption and impaction of the successor teeth.

Conflict of Interest

Nil

Acknowledgement

Nil

Authors' Biography

Dr. Neelesh Gautam postgraduation, Dr. Updesh Masih Professor and Head/Guide, Dr. Akshada Chougankar postgraduation.

References

1. Bjerklin K, Bennett J. The long-term survival of lower second primary molars in subjects with agenesis of the premolars. *Eur J Orthod* 2000; 22(3): 245-55.
2. Ith-Hansen K, Kjaer I. Persistence of deciduous molars in subjects with agenesis of the second premolars. *Eur J Orthod* 2000; 22(3): 239-43.
3. Haselden K, Hobkirk JA, Goodman JR, Jones SP, Hemmings KW. Root resorption in retained deciduous canine and molar teeth without permanent successors in patients with severe hypodontia. *Int J Paediatr Dent* 2001; 11(3): 171-8.
4. Burch J, Ngan P, Hackman A. Diagnosis and treatment planning for unerupted premolars. *Pediatr Dent* 1994; 16(2): 89-95.
5. Robinson S, Chan MF. New teeth from old: Treatment options for retained primary teeth. *Br Dent J* 2009; 207(7): 315-20.
6. De Coster PJ, Marks LA, Martens LC, Huysseune A. Dental agenesis: Genetic and clinical perspectives. *J Oral Pathol Med* 2009; 38(1): 1-17.
7. Joshi MR. Transmigrant mandibular canines: A record of 28 cases and a retrospective review of the literature. *Angle Orthod* 2001; 71(1): 12-22.
8. Aktan AM, Kara I, Sener I, et al. An evaluation of factors associated with persistent primary teeth. *Eur J Orthod* 2011; 10: 1-5.:
9. Nikiforuk G. Ectopic Eruption: Discussion and clinical report. *J Ont Dent Assoc.* 1948 Jun; 25:243-6.