

Therapeutic Management of Cytauxon Felis in Cat

Suryawanshi A. A¹, Patil.J. U², Gaikawad R. V³

¹Department of Teaching Veterinary Clinical Complex

²Department of Clinical Medicine, Ethics and Jurisprudence

³Department of Veterinary Epidemiology and Preventive Medicine, Mumbai Veterinary College, Parel, Mumbai-400012.

Abstract

The Parel campus of the Mumbai Veterinary College in Mumbai, Maharashtra, received a delivery of a Persian cat that was 4 months old and weighed 2 kg. Past instances of pyrexia, anorexia, and physical weakness. Clinical examination revealed the patient was dehydrated, anemic, and had a high temperature (104.3°F). A complete blood count, liver function tests, and kidney function tests all show low hemoglobin, a low platelet count, and increased liver enzyme levels. The cat was first given injections of oxytetracycline at a dose of 10 mg/kg body weight for three days, after which susp. azithromycin at a dose of 10 mg/kg B.W. and tab. atovaquone at a dose of 15 mg/kg B.W. along with fluid treatment, injections of acetyl-cysteine at a dose of 140 mg/kg, and finally reduction to 50 mg/kg were given.

Keywords: *Cytauxon felis*, Cat, Azithromycin, Atovaquone, Acetyl-cysteine.

Introduction

The apicomplexan hemoparasite *Cytauxoon* species can infect lions, tigers, domestic cats, and cause them to become critically ill. The most typical tick vector in the United States is the lone star tick, *Amblyomma americanum*, while other ticks have the capacity to spread disease (Reichard et al., 2010). Cytozoonosis (*C. felis*) frequently presents in the USA as an acute or subacute, very febrile sickness. The non-specific clinical symptoms include vocalization, anorexia, high fever, icterus, dyspnea, tachycardia, widespread pain, and depression. Hemolytic anemia frequently manifests as pale mucous membranes, pigmenturia, splenomegaly, and hepatomegaly (Lloret et al., 2015).

Resources and Procedures

The present study was conducted in the department of teaching veterinary clinical complex (TVCC), Mumbai Veterinary College, Parel, Mumbai.

1. Clinical history

A Persian cat that was 4 months old and weighed 2 kg was brought to the Parel campus of the Mumbai Veterinary College in Mumbai, Maharashtra. Anorexia, pyrexia, and bodily weakness in the past.

1. Clinical and laboratory examination

Clinical evaluation revealed the patient had a high temperature (104.3°F), was anemic, looked dull, and was dehydrated. High WBC count and liver enzyme values are shown by a complete blood count, liver function test, and kidney function test.

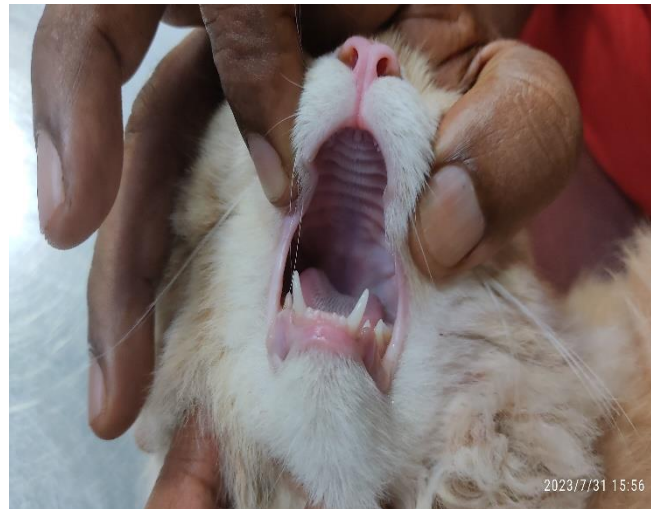

Fig. 1: Slight Pale Mucus Membrane of Cat

Results and Discussion

During a blood smear investigation, *Cytauxon felis* was discovered in the case (Fig. 2). The haemato-biochemical investigation revealed low Hb, TEC, PCV, and platelet counts (Table 1). RBC rupture results in a significant rise in total bilirubin, direct and indirect bilirubin, and AST, all of which are signs of pre-hepatic jaundice. Cohn et al. (2011) found comparable outcomes for anemia, thrombocytopenia, and hyperbilirubinemia.

Therapeutic Management

The cat was initially treated with inj. Oxytetracycline @ 10 mg/kg B.W. for 3 days and shifted to susp. Azithromycin @ 10mg/kg B.W.

Sr. No.	Parameter	Day 1	Day 20	Reference Range
1	Hb (g %)	8.9	9.4	9.5 - 15.0 gm %
2	TEC (million/cmm)	5.05	6.46	6.0 - 10.0 million / cmm
3	PCV (%)	21.4	26.7	29.0 - 45 %
7	TLC (thousand/cmm)	8.41	14.12	5.5 -19.5 x 10 ³ / cmm
8	Neutrophils (%)	89	76	35 - 75 %
9	Lymphocyte (%)	09	20	20 - 55 %
10	Monocyte (%)	01	02	01 - 04 %
11	Eosinophil (%)	01	02	02 - 12 %
13	Platelets(thousand/cmm)	73000	225000	150000 - 600000 /cmm
14	Total bilirubin (mg/dl)	3.83	0.2	0 - 0.4 mg/dl
15	Direct bilirubin (mg/dl)	2.11	0.1	0.0 - 0.1 mg/dl
16	Indirect bilirubin (mg/dl)	1.72	0.1	0 - 0.3 mg/dl
17	AST (IU/L)	73.2	25	05 - 55 IU/L
18	ALT (IU/L)	46.6	106	28 - 76 IU/L
19	Albumin (g/dl)	2.98	2.9	2.4 - 4.1 g/dl

20	Globulin (g/dl)	4.57	3.40	3.4 - 5.2 g/dl
21	Total Protein (g/dl)	7.55	6.3	5.9 - 8.5 g/dl
22	Blood Urea Nitrogen	16.12	16.2	15 - 34 mg/dl
23	Serum creatinine (mg %)	0.7	0.9	0.8 - 2.3 mg/dl

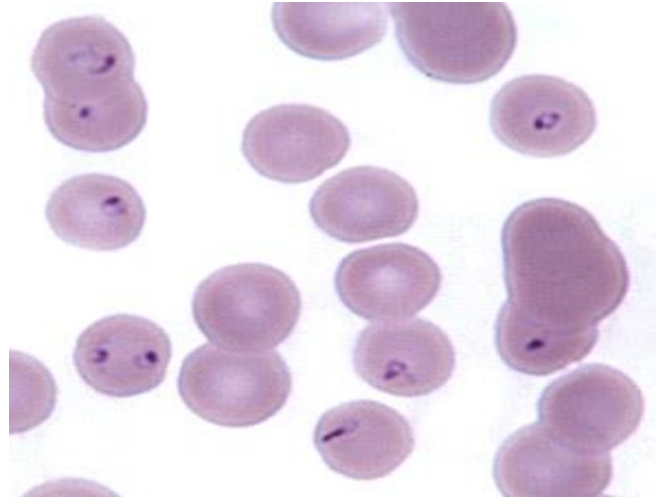


Fig. 2: Merozoites of *Cytauxxon felis*

plus Tab. Atovaquone @ 15 mg/kg B.W. per orally along with fluid therapy, inj. Acetyl-cysteine @ 140 mg/kg and then reduce to 50mg/kg B.W., multivitamins and pre-probiotic orally. Cat showed complete recovery after 20 days of therapy.

Similar findings by Cohn *et al.*, (2011) reported that a 53 cats treated with Azithromycin and Atovaquone, 32 (60%) survived to discharge while only 7 of 27 cats (26%) treated with imidocarb survived. Cats with a lower parasitemia were more likely to survive, as were cats with higher white blood cell counts and lower total bilirubin. According to Wang *et al.*, (2017), Atovaquone with Azithromycin is considered the most effective treatment for acute infection. Similar suggestions given by Pacholec *et al.*, (2020) Atovaquone 15 mg/kg PO q8h for 10 days,

References

1. Cohn L.A., Birkenheuer A.J., Brunker J.D., (2011). Efficacy of Atavaquone and Azithromycin or imidocarb dipropionate in cats with acute cytauxzoonosis. *J Vet Intern Med*; **25**: 55–60.
2. Lloret A., Addie D.D., Boucraut-Baralon C., Egberink H., Frymus T., Gruffydd-Jones T., Hartmann K., Horzinek M.C., Hosie M.J., Lutz H., Marsilio F., Pennisi M.G., Radford A.D., Thiry E., Truyen U., Möstl K. (2015). European Advisory Board on Cat Diseases. Cytauxzoonosis in cats: ABCD guidelines on prevention and management. *J Feline Med Surg.* (7):637-41. doi: 10.1177/1098612X15589878. PMID: 26101317.
3. Pacholec C., Cohn L. A., (2020). Cytauxzoonosis in cats. Today’s veterinary practice. Cited on <https://todaysveterinarypractice.com/parasitology/cytauxzoonosis-in-cats/>
4. Reichard M.V., Edwards A.C., Meinkoth J.H., (2010). Confirmation of *Amblyomma americanum* (Acari: Ixodidae) as a vector for *Cytauxzoon felis* (Piroplasmorida: Theileriidae) to domestic cats. *J Med Entomol.* **47**(5):890-896.

5. Wang J-L, Li T-T, Liu G-H, Zhu X-Q, and Yao C. (2017). Two tales of *Cytauxzoon felis* infections in domestic cats. *Clinical Microbiology Review* **30**:861–885. <https://doi.org/10.1128/CMR.00010-17>