

Natural Therapy of Cutaneous Leishmaniasis

Khalifa A A Fatnasa¹, K Abdulhamed Alkout A²

¹Faculty member of Medical technology at Higher Institute of Science and Technology in Tiji city, Libya

²Faculty member of Medical technology at University of Tripoli, Tripoli city, Libya

Abstract

Leishmaniasis is a parasitic disease that is spread by the bite of phlebotomine sand flies, there are several different forms of leishmaniasis in people, the most common forms is cutaneous leishmaniasis, and visceral leishmaniasis, Cutaneous leishmaniasis is characterized by one or more cutaneous lesions, which can change in size and appearance over time, the skin sores of **Cutaneous leishmaniasis** usually heal on their own, even without treatment, but this can take months or even years. A recent study has lead to new natural treatment to accelerate the healing time of lesions caused by leishmania parasite, which based on using a bandage of banana peels at the lesions site during night for seven to ten days. There were eight cases out of ten have responded positively to using banana peels and completely cured, and two did not respond. Patients who have the injection treatment is healed in short time in compare to one who did not take injection.

Keywords: leishmaniasis, banana peels, sand flay.

Introduction

Leishmaniasis is a disease, caused by a protozoan parasite of the genus *Leishmania*, and transmitted by a bite of infected female sand flies (1). Genus *phlebotomus* in the old world and the genus *Lutzomyia* in the new world (2). It is Prevalent in 98 countries and regions of the world which responsible for increasing health problems (3).

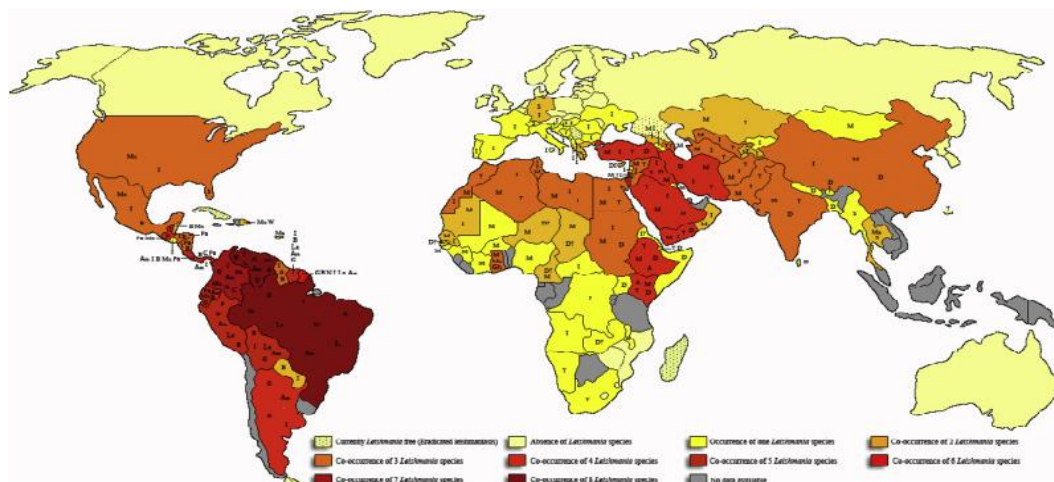


Figure (1) Geographical distribution of *Leishmania* sp (7).

The cutaneous leishmaniasis (CL) include a spectrum of self healing and chronic disease forms, the Clinical presentations differ according to parasite burden and host immune response(6). The patients with cutaneous leishmaniasis present with a papule or nodule at the site of inoculation, followed by formation of crusts, which causes skin sores. There are various procedures and laboratory techniques used to diagnose leishmaniasis, punch skin biopsy is widely used & popular technique(1). The diagnosis of CL is based on clinical features (supported by epidemiologic data) and laboratory testing, numerous diagnostic methods have been described with a huge variation in diagnostic accuracy, including direct parasitologic examination (microscopy, histopathology, and parasite culture) and/or indirect testing with serology and molecular diagnostics (9). Different drugs like sodium stibogluconate, sodium antimony gluconate, Amphotericin B and Miltefosine: are used for its treatment (1).

Amphotericin B injection in a dose of 25 mg in 5% dextrose can be administered intravenously 6 hourly with a total dose of 1980 mg (1). Pentavalent antimonials, Intra lesional infiltration of 1-5 ml (100 mg/ml) sodium stibogluconate (SSG) can be given to patients with cutaneous leishmaniasis on alternate days for three days once a month and this results in complete healing by the end of second month in most cases (4).

Cutaneous leishmaniasis in Libya

Zoonotic cutaneous leishmaniasis, caused by leishmania .*major*, which is the main type of leishmaniasis in the country. The number of cases has progressively decreased since the implementation of control activities at the end of 2006 and probably also due to protective immunity in the populations affected. Control measures mainly consisted of reducing the rodent population and using vector control techniques by local pest management companies. The national control programme for leishmaniasis in Libya is well established and structured. It has managed to eliminate 85%–90% of the *Psammomys* population, the animal reservoir, in the targeted areas (8).

Prophylactic vaccines

There is no vaccine against leishmaniasis, although, intradermal inoculation of live virulent *L. major* promastigotes has been used to protect against *L. major* infection(5).

Control of leishmaniasis

The best way for travelers to prevent infection is to protect themselves from sand fly bites and to decrease the risk of being bitten, by Avoid outdoor activities, especially from dusk to dawn, when sand flies generally are the most active(7). The national center for disease control in Libya are doing the best to control and decrease the prevalence of leishmania parasite infections in Libya by making awareness campaigns throughout endemic area in all regions(8).

Banana peels

Banana peel was able to draw attention as a source of functional and nutritional compounds, for biological activities of banana peel as antioxidant and antimicrobial activities as a result of containing compounds as, Phenolic compounds, alkaloids, flavonoids, tannins, saponins, glycosides, carotenoids, sterols, triterpenes, and catecholamine.

Future studies are required to determine the biologically active compounds, potentials, and multiple benefits hoped for banana peel instead of being a neglected waste (12).

For making wound dressing, the banana part used is peel, this is because lignin affect (10). Banana helps the formation of peels compound so it can be used to treat, burns, bruises, and skin infections(11).

The banana peels also contains other substances as fatty acids, and carotenoids, which have proved antioxidant activity (12).

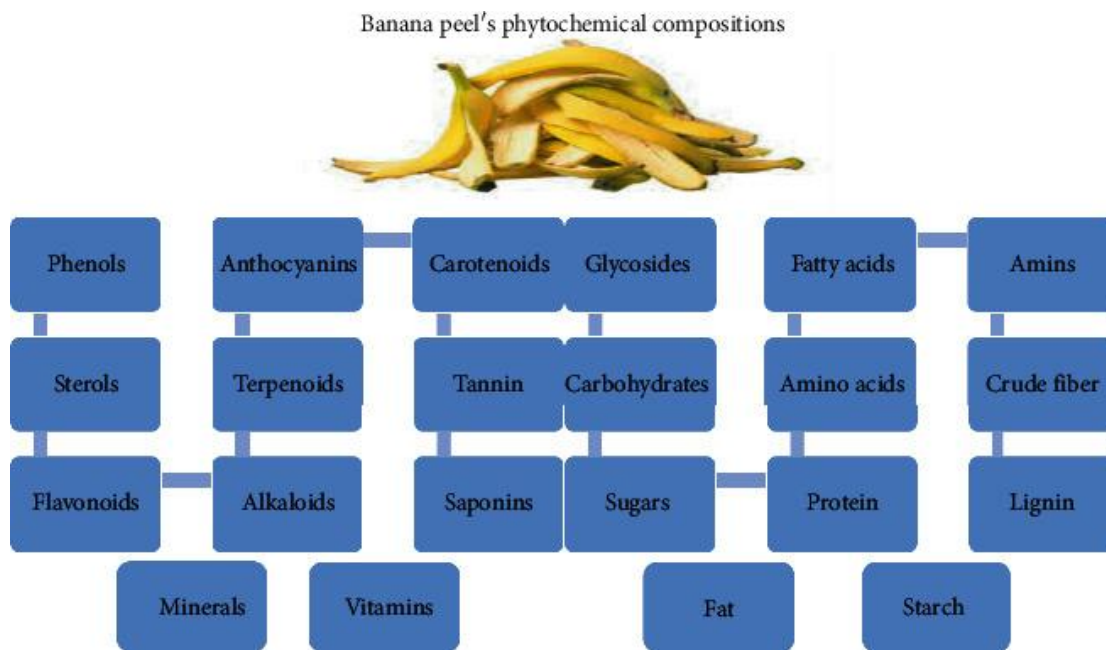


Figure (2) The chemical compositions of banana peels (13).

Material and methods

Treating leishmania infection is not hard, although it takes time to heal completely and may leave scar. Recently we have come up with trial has been successful to help and heal infection, the trial steps are very simple, it based on using banana peels nightly for seven to ten nights as bandage, based on the progress of parasitic infection, the peels of banana used directly on the lesion of leishmania infection, even, the patients who have the infection can apply the peels of banana with himself every night. Peels that have been collected, washed with water to remove dirt, and cut into small pieces and then used as bandage.

Banana peels , bandage, 70% alcohol, gloves, Distilled water all are used in the trial

Result and discussion

Using banana peels on the lesion is successful method to cure leishmania parasite infection, especially if the patient had the injection treatment, as it is shown in figure (3,4) which illustrate how banana peels successful in healing the lesion jus in six days.

After the trials we have done, eight cases have responded and healed completely, but two have not responded, and healed partially, by partially we mean their infection symptom have relived.

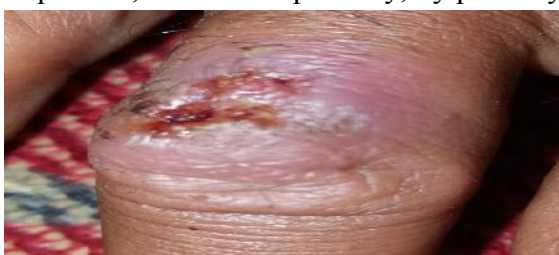

Figure (3) lishmaniasis infections on finger

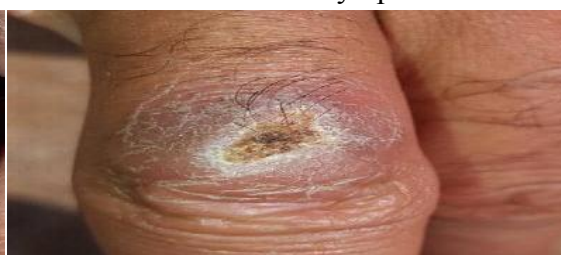

Figure (4) lishmaniasis infection after using banana peels

Leishmania parasite infection is hard to cure in short time, especially the scar on the skin that left after healing, that scar totally disappear after using the banana on the lesion in some cases, especially if the infection in the beginning or the patient had the injection treatment, also it can help in reliving symptoms of leishmania infection such as cramping, fever and bleeding .

The patients who had the leishmania parasite treatment injection is quicker to heal than one who did not take the injection, also infection in the beginning more successful to respond as it shown in the table (1) and figures (3,4).

Table (1) explain the results of the trail.

Cases No	injection	Using banana peels	Days to heal	early stage	Late stage	sex	age
1	used	successful	3-6 days	yes		male	30
2	No used	weak response	After 7 days		yes	male	32
3	used	successful	5-7 days		yes	male	22
4	used	successful	5-8 days	yes		male	29
5	Not used	No response	none		yes	male	35
6	used	successful	3-4 days	yes		male	36
7	used	successful	After 9 day	yes		female	24
8	used	successful	After 7 days	yes		female	11
9	Not used	no response	none		yes	male	40
10	used	successful	After 10 days		yes	female	27

Acknowledgement

we would like to express our sincere gratitude to the ten cases who volunteered to do the banana peels trial and all who helped us even with consultations.

References

- 1- Adhikari Ram Chandra, Shah Mahesh. Cutaneous leishmaniasis. Journal of Pathology of Nepal (2017) Vol. 7, 1212-1117.
- 2-Hashiguchi Y, Velez LN, Villegas NV, Mimori T, Gomez EA, Kato H. Leishmaniasis in Ecuador: comprehensive review and current status. Acta Tropica 2017;166:299-315.
- 3- Alvar J, Velez ID, Bern C, et al. Leishmaniasis worldwide and global estimates of its incidence. WHO leishmaniasis control team. 2012; PLUS one 7 e35671.
- 4- Sharma NL, Mahajan VK, Kanga A, et al. Localized cutaneous leishmaniasis due to *Leishmania donovani* and *Leishmania tropica*: Preliminary findings of the study of 161 new cases from a new endemic focus in Himanchal Pradesh, India. Am J Trop Med Hyg 2005;72:819-24.
- 5- WHO technical report series 949. Control of the leishmaniasis, Report of a meeting of the WHO expert committee on the control of leishmaniasis. 2010; 1-179.
- 6- . Convit J, Ulrich M, Fernandez C, et al. The clinical and immunological spectrum of American cutaneous leishmaniasis. Trans R Soc Trop Med Hyg 1993;87:444- 448.
- 7-<http://www.CDC.gov.parasite.leishmaniasis.prevent>.
- 8- <https://www.emro.who.int/neglected-tropical-diseases/countries/cl-libya.html>.
- 9- Goto H, Lindoso JA. Current diagnosis and treatment of cutaneous and mucocutaneous leishmaniasis. *Expert Rev Anti Infect Ther*. 2010;8(4):419–433. doi: 10.1586/eri.10.19.
- 10- wina E 2001, Tanaman pisang. Sebagipakan. Ternak Ruminan Asia. Balai penelitian Ternak. Wartazwa vol 11 1.
- 11-<https://www.researchgate.net-publications>.
- 12- Atzingen DANCV. 2011. Gel from unripe *Musa sapientum* peel to repair surgical wounds in rats. Acta Cir. Bras., São Paulo, v. 26, n. 5, Oct.
- 13- Wafaa M. Hikal, Hussein A. H. Said-Al Ahl, Amra Bratovic, Kirill G. Tkachenko, Javad Sharifi-Rad, Miroslava Kačániová, Mohammed Elhourri, and Maria Atanassova. Banana Peels: A Waste Treasure for Human Being. Evid Based Complement Alternat Med. 2022; 2022: 7616452.