

A Unique Clinical Approach to Diagnose a Rare Case of Polycythemia

Vipul Rawlani¹, Sakshi Sharma², Prasanth P³, Amit Aggarwal⁴,
Himanshu Sikri⁵

^{1,2}Postgraduate Student, ABVIMS and Dr. RML Hospital, New Delhi.

³Senior Resident, ABVIMS and Dr. RML Hospital, New Delhi.

⁴Senior Specialist, ABVIMS and Dr. RML Hospital, New Delhi.

⁵Senior Medical Officer, ABVIMS and Dr. RML Hospital, New Delhi.

Abstract:

Primary familial and congenital polycythemia (PFCP) is a rare autosomal dominant disorder caused by hypersensitivity of erythropoietin receptor leading to increased rate of erythropoiesis at any given serum erythropoietin level.

Thrombosis contributes to severe morbidity and mortality in cases of primary erythrocytosis due to any cause.

Primary erythrocytosis or autonomous production of excess erythrocytes occurs mostly due to myeloproliferative neoplasms like polycythemia vera (PV) but can rarely occur in familial conditions also. Even though it does not come under myeloproliferative neoplasm, it can still lead to severe morbidity and early mortality due to increased chances of thrombotic events. However, unlike polycythemia vera, leukemic transformation and myelofibrosis is not seen.

Here, we present case of a 33 year old male who presented with both arterial and venous thrombosis and was then diagnosed as non – clonal primary erythrocytosis which was presumably familial as his son was also found to have erythrocytosis.

Diagnosing this fatal condition is essential ; as PFCP has autosomal dominant inheritance and early recognition in family can prevent further vascular events in other family members as well.

CASE PRESENTATION

A 33-year-old healthy male, with no smoking history, normal body mass index, and a varied diet, presented with sudden weakness in his right upper and lower limbs, accompanied by facial deviation. He was last seen normal the night before. Upon examination, his blood pressure was elevated at 160/100 mmHg, with a consistent pulse rate of 90 beats per minute and oxygen saturation of 98%. Although conscious, he appeared drowsy, with otherwise unremarkable systemic findings.

An urgent NCCT head scan revealed an acute infarction in the territory of the left middle cerebral artery, with an ASPECT score of 9/10. Fundoscopic examination ruled out signs of increased intracranial pressure. Subsequently, the patient was commenced on antiplatelet therapy and a statin regimen. Initial laboratory investigations revealed a high hemoglobin level of 19.7 g/dL, hematocrit of 67.5%, and elevated red blood cell count of 6 million/mm³, consistent with polycythemia. Other blood parameters,

including leukocyte and platelet counts, were within normal ranges. Electrocardiography and 2 D ECHO findings were unremarkable.

Given the persistence of polycythemia on repeat testing, therapeutic phlebotomy was initiated following adequate hydration with intravenous fluids. Patient had persistent headache with obvious worsening of sensorium; a repeat NCCT head was done which showed infarct in the right Anterior Coronary Artery territory also; During the course of hospital stay; a right internal jugular central venous catheter was secured; soon after which patient started developing swelling in the right upper arm. Venous doppler study for the right upper limb was done which showed thrombosis of the superficial venous system.

Patient was worked up for his conditions with emphasizing issues being -

1. Arterial plus venous thrombosis
2. Polycythemia

Peripheral smear analysis revealed a normocytic picture, with a single central spike evident in the RBC histogram. Coagulation profiles demonstrated normal INR and APTT (1.03 and 32.6 seconds respectively), along with elevated fibrinogen and D-dimer levels (367 mg/dl and <250 ng/ml respectively). Serum homocysteine levels were mildly elevated [26.1 mmol/L (Normal <15 mmol/L)], while vitamin B12 (800 pg/ml) and folate levels (8.77ng/ml) were within normal limits. Testing for MTHFR gene mutation and Factor V Leiden mutation yielded negative results. Antiphospholipid antibody (APLA) testing revealed positive IgM and IgG anti-cardiolipin antibodies with high titers (>40 IU/ml) persisting over 12 weeks. Notably, autoimmune workup, including ANA and vasculitic profile, returned negative results. Interestingly, EPO levels were significantly reduced [2.93 mU/ml (N : 5.5 – 28)] contradicting the initial suspicion of polycythemia vera, especially in the absence of thrombocytosis. Additionally, the patient developed thrombocytopenia after the initial hospitalization period, further complicating the diagnostic landscape. JAK2-V617F was ordered along with EXON 12 mutation. Following the negative results for JAK2-V617F and EXON 12 mutation, a bone marrow examination was pursued. The bone marrow aspirate revealed normal tri-lineage hematopoiesis, with the erythroid series exhibiting predominantly normoblastic maturation, alongside unremarkable myeloid and megakaryocytic lineages. USG Abdomen showed normal liver and spleen with no any significant abnormality. Thyroid profile was also normal.

Literature was reviewed other causes of polycythemia were searched for in the patient. High affinity hemoglobins were suspected ; A High Performance Liquid Chromatography was done which showed normal proportions of HbA ; A2; HbF<1% ; Venous Blood Gas done showed pH : 7.380 ; pO₂ : 50; SO₂ : 84.9 ; P50 came to be normal i.e >27 hence ruling out high affinity hemoglobins (which was also supported by low erythropoetin levels). Meanwhile patients condition which initially deteriorated improved subsequently; he was put off ventilatory support but he had persistent unexplained tachycardia with hypoxemia; Chest x-ray and ECG examination were normal. So, CT pulmonary angiogram was done which showed thrombus in the lateral basal segmental artery of right lower lobe pulmonary artery with associated infarct in the supplied territory.

Despite exhaustive laboratory investigations, no definitive cause for polycythemia was identified. Therefore, the diagnosis was established as primary polycythemia, accompanied by antiphospholipid antibody syndrome (APLA) and mild hyperhomocysteinemia. Plans to conduct a study for EPO-receptor mutation were hindered by logistical challenges within our institute.

Given the potential familial nature of polycythemia, a complete blood count was performed on the patient's 13-year-old son. Results revealed a hemoglobin level of 16.5 g/dL and a hematocrit of 55.6%, notably elevated for his age. Further analysis demonstrated a total leukocyte count of 6000 and a platelet count of

1.7 lakhs/cu.mm, alongside RBC indices indicating microcytosis. Subsequent CBCs consistently indicated elevated hematocrit levels. Erythropoietin levels were measured and found to be low at 4 mU/mL, deviating from normal values. These findings underscore the potential hereditary component of primary polycythemia, prompting ongoing surveillance and management for both the patient and his son. As father-son duo had the same problem of erythrocytosis, so a final diagnosis of primary familial and congenital polycythemia was made with APLA and mild hyperhomocysteinemia. Patient was finally discharged on Vitamin K antagonists and antiplatelets; His son was also advised for close hematological follow-up and for requirement of prophylactic phlebotomy.

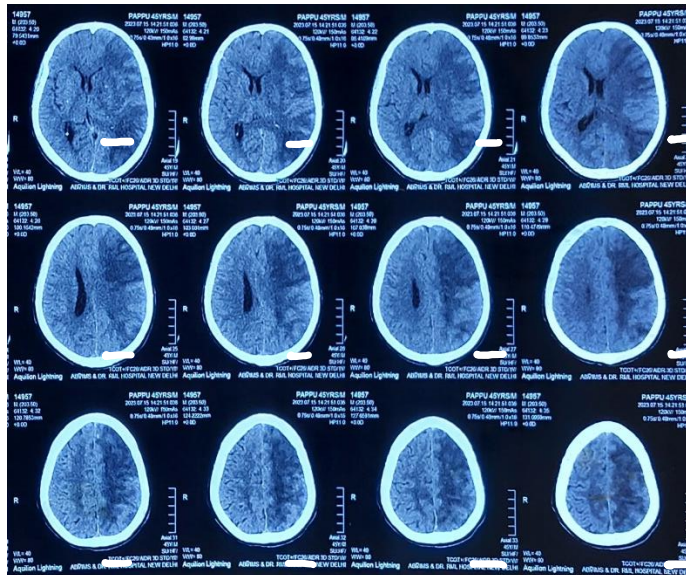


Fig.1 NCCT Head showing a large infarct in the left MCA territory at admission.

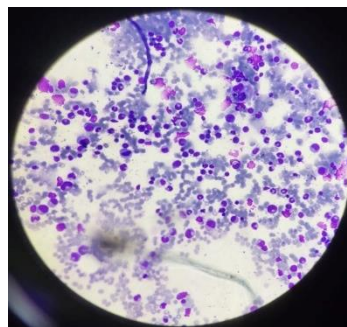


Fig.-2 showing bone marrow aspirate with trilineage hematopoiesis with erythrocytic lineage showing predominantly normoblastic picture.

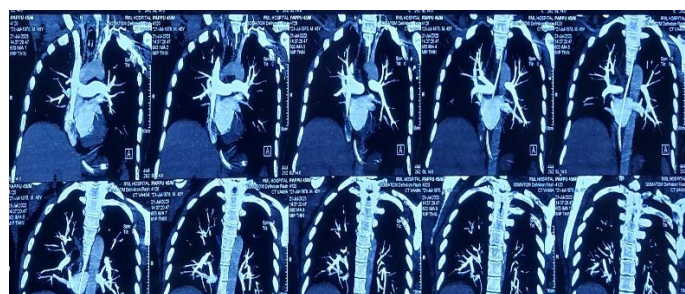


Fig.-3 showing CT-Pulmonary angiogram with filling defect (s/o thrombus) in right lower lobe pulmonary artery.

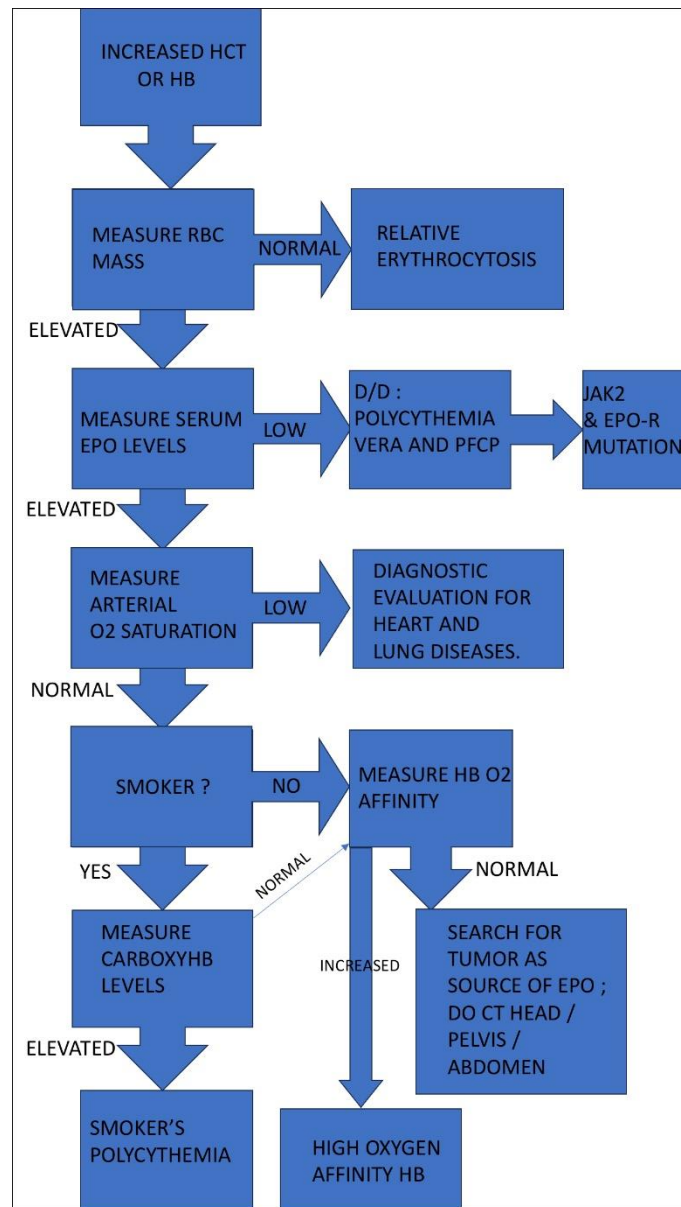


Fig.- 4 showing simplified approach to polycythemia.

DISCUSSION

Primary familial and congenital polycythemia (PFCP) presents a diagnostic challenge due to its resemblance to other conditions and potential for misdiagnosis. Thrombotic events are less commonly reported in PFCP compared to polycythemia vera (PV), emphasizing the importance of a thorough step-by-step approach in evaluating polycythemia cases to ensure accurate diagnosis and appropriate management.(1)

As in our case a case reported by Sokol et al. where a 24 year old male patient was diagnosed with the similar condition where subsequently his his children were also diagnosed with the same condition along with his mother. (2) The prevalence of PFCP is not known. To date, PFCP caused by inherited heterozygous pathogenic variant in EPOR has been reported in 116 individuals and 24 families. (3)

For all patients with polycythemia, initial measures such as hydration or intravenous fluids are crucial to exclude relative erythrocytosis. Subsequent assessments should include a repeat complete blood count (CBC) to confirm persisting polycythemia. Patients should be thoroughly assessed for symptoms such as

headache, visual disturbances, bone pain, palpitations, and hypertension, and a comprehensive physical examination is imperative.(1)While Western literature often recommends RBC mass measurement to exclude relative erythrocytosis, the availability of this test can be limited. Therefore, after adequate hydration and repeat CBC, direct evaluation of serum erythropoietin levels is recommended. (4)Low serum erythropoietin levels are indicative of either polycythemia vera (PV) or PFCP. (5)Further genetic testing, including JAK-2 mutation analysis and examination for EPOR gene mutations, is warranted in cases of reduced erythropoietin levels.(6)

Abdominal ultrasound can aid in distinguishing PV from PFCP by identifying hepatosplenomegaly, a feature typically absent in PFCP. Moreover, PV often presents with thrombocytosis alongside erythrocytosis, with the latter being predominantly microcytic, unlike the macrocytic presentation observed in our case, which argues against PV.(7) For patients with elevated erythropoietin levels, arterial blood gas (ABG) analysis is recommended to assess for heart and lung disease. (8)Additional investigations such as carboxyhemoglobin levels, assessment of hemoglobin oxygen affinity, and comprehensive tumor screening should also be considered to rule out secondary causes of erythrocytosis. A simplified diagnostic algorithm can streamline the workup for polycythemia, ensuring timely and accurate diagnosis, as depicted in Figure 4.

CONCLUSION

A systematic approach to the evaluation and management of polycythemia is essential, particularly in identifying rare disorders like PFCP, which require tailored therapeutic strategies and family-oriented care to optimize patient outcomes and prevent complications.

Management of PFCP involves patient education ; screening of other family members ; avoiding factors precipitating erythrocytosis such as smoking ; high altitude.

Phlebotomy is indicated if patient has features of hyperviscosity to maintain HCT lower than 45 %. (9)

CONFLICT OF INTEREST

Nil.

ACKNOWLEDGEMENT

I would like to extend my heartfelt thanks to Dr. Vishakha Mittal for her invaluable assistance and guidance in diagnosing our cases.

REFERENCES

1. Gordeuk VR, Key NS, Prchal JT. Re-evaluation of hematocrit as a determinant of thrombotic risk in erythrocytosis. *Haematologica*. 2019;104(4).
2. Sokol L, Luhovy M, Guan Y, Prchal JF, Semenza GL, Prchal JT. Primary familial polycythemia: A frameshift mutation in the erythropoietin receptor gene and increased sensitivity of erythroid progenitors to erythropoietin. *Blood*. 1995;86(1).
3. Bento C, Percy MJ, Gardie B, Maia TM, van Wijk R, Perrotta S, et al. Genetic Basis of Congenital Erythrocytosis: Mutation Update and Online Databases. *Hum Mutat*. 2014;35(1).
4. Sirhan S, Fairbanks VF, Tefferi A. Red cell mass and plasma volume measurements in polycythemia: Evaluation of performance and practical utility. *Cancer*. 2005;104(1).

5. Aljabry M. Primary familial and congenital polycythemia; The forgotten entity. *Journal of Applied Hematology*. 2018;9(2).
6. Jedlickova K, Stockton DW, Prchal JT. Possible primary familial and congenital polycythemia locus at 7q22.1-7q22.2. *Blood Cells Mol Dis*. 2003;31(3).
7. Spivak JL. Narrative review: Thrombocytosis, polycythemia vera, and JAK2 mutations: The phenotypic mimicry of chronic myeloproliferation. Vol. 152, *Annals of Internal Medicine*. 2010.
8. Haymond S, Cariappa R, Eby CS, Scott MG. Laboratory assessment of oxygenation in methemoglobinemia. In: *Clinical Chemistry*. 2005.
9. Prchal JT, Sokol L. "Benign erythrocytosis" and other familial and congenital polycythemias. Vol. 57, *European Journal of Haematology*. 1996