

Pulpotomy with Human Amniotic Membrane in Case of Irreversible Pulpitis: Case Series

Rimpy Mehra¹, Tanvi Thakur², Ashu Gupta³, Neha Sharma⁴

^{1,2}Post Graduate Student, HPGDC, Shimla

³Principal, HPGDC, Shimla

⁴Senior Lecturer, HPGDC, Shimla

ABSTRACT:

The aim of this study was to evaluate the outcome of human amniotic membrane as pulpotomy agent in permanent molars. Patients with diagnosis of irreversible pulpitis in mandibular molars of age group 18 to 49 years were selected and human amniotic membrane (hAM) was selected as pulpotomy agent as it is one of the biologically derived natural pulpotomy agent which may serve as better alternative for treating irreversible pulpitis. This case series consists of 4 patients treated with hAM as pulpotomy agents.

KEYWORDS: pulpotomy, amniotic membrane, irreversible pulpitis

INTRODUCTION

According to Finn (1995), pulpotomy is defined as the complete removal of coronal portion of the dental pulp, followed by the placement of the suitable dressing or medicament that will promote healing and preserve the vitality of the tooth.

Managing inflamed pulp with pulpotomy is advantageous as it maintains pulp developmental, defensive and proprioceptive functions (Paphangkorakit & Osborn, 1998).

The newly introduced hAM is the innermost layer of fetal membrane of thickness 0.02 mm to 0.5 mm.^[1] Davis et al reported its first use in skin transplantation in 1910.^[2]

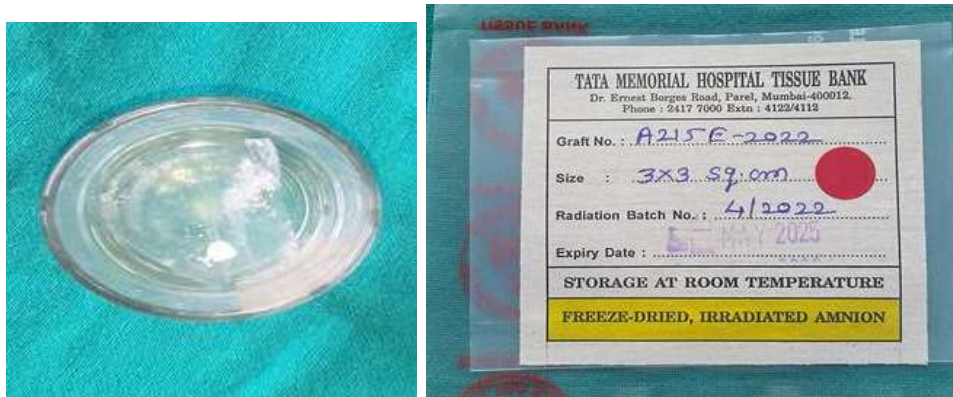AM possesses anti-inflammatory, antibacterial, antiviral nature and has ability to form scaffolds. It is obtained from the freeze-dried placenta at -60°C under vacuum and sterilized using 2.5 megarads radiation in cobalt-60 irradiator.

AM role in endodontics is not yet studied much. Therefore, this case series aims and evaluate the role of amniotic membrane as a pulpotomy agent.

CASE PRESENTATION 1:

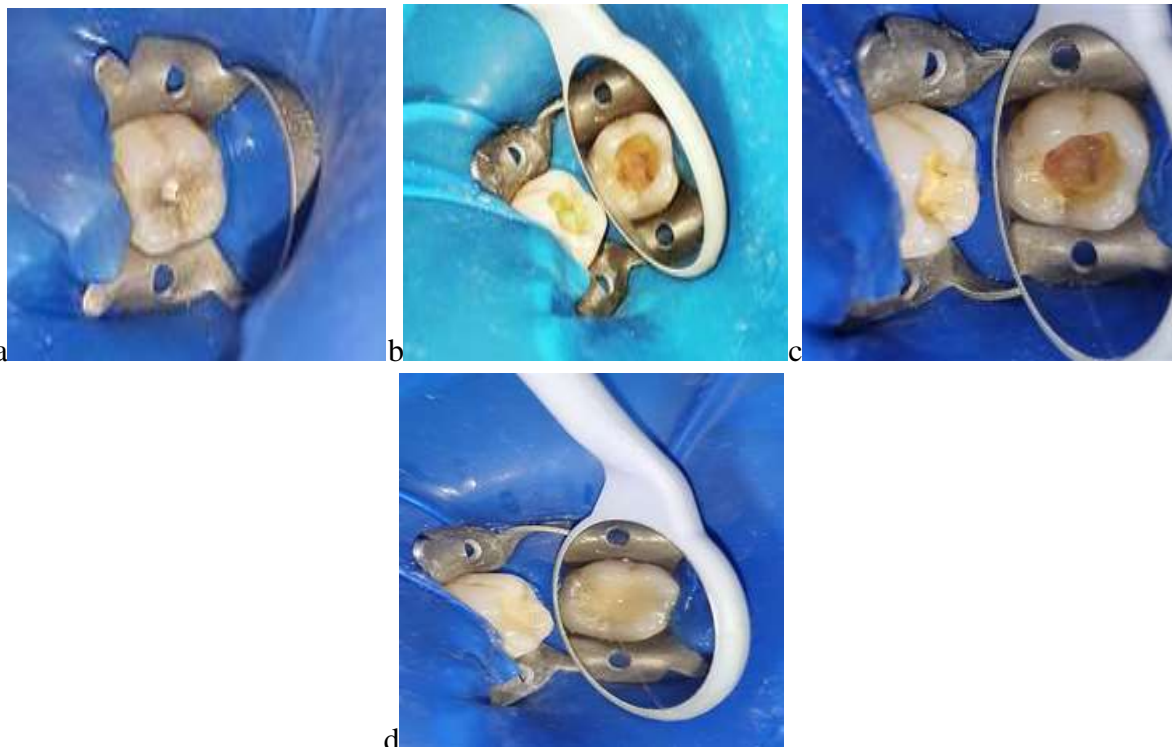
- Patient of age 22 yrs, with insignificant medical history reported to HPGDC, Shimla with chief complaint of pain and sensitivity in her lower jaw from 1 month. Clinical examination revealed the presence of an occlusal, moderately sized (according to IES classification), carious exposure of her lower right permanent molar. Pulp sensibility test revealed lingering pain to the application of cold. No associated sinus and tenderness on percussion present. On Radiographic examination a large coronal radiolucency, approaching the pulp was seen. A diagnosis of irreversible pulpitis was made. After obtaining consent, complete coronal pulpotomy was planned with hAM as the therapeutic agent.

- Anaesthesia was achieved containing 2% lignocaine then rubber dam was applied and access cavity was prepared. Caries excavation was done with spoon excavator and coronal pulp tissue was removed till the root canal orifices. Then bleeding was stopped with sterile cotton pellet dipped in saline for 5 minutes. After that hAM (procured from Tissue bank, Tata Memorial Hospital, Mumbai, India) was placed in the chamber after activation in saline for 1 minute.

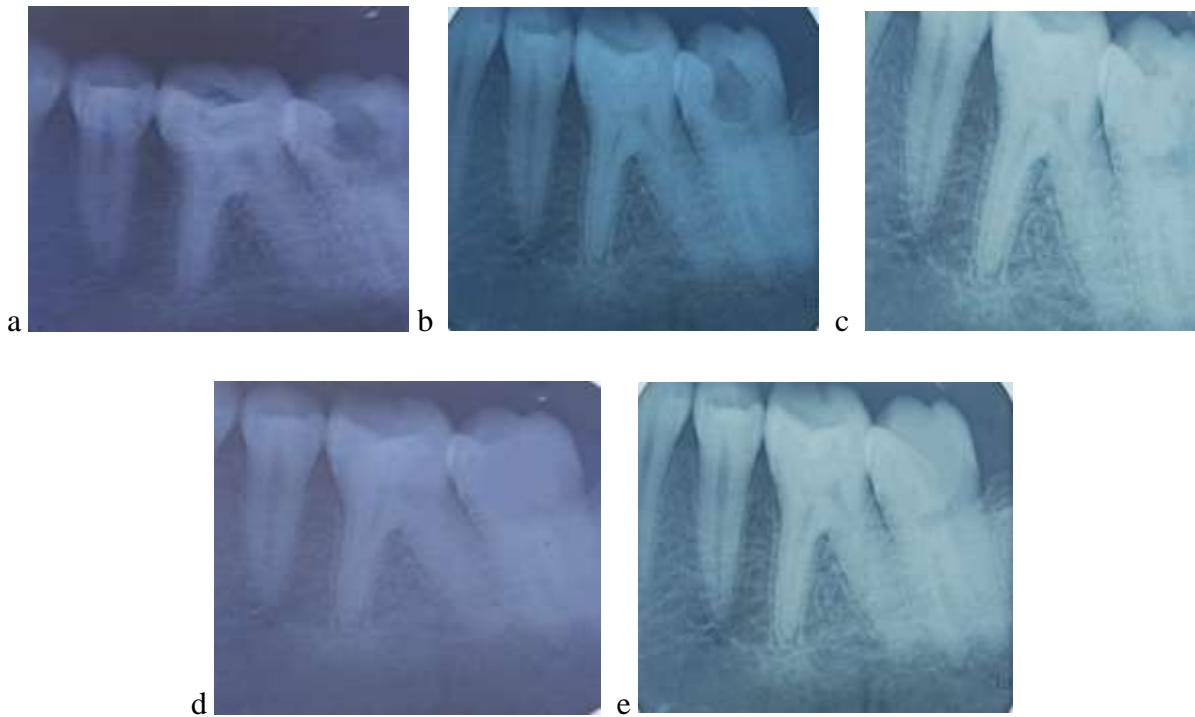


Activation of hAM

- AM was gently placed in chamber with thickness of 2-3mm and restorative cement (type II GIC) was placed gently without any pressure. Post operative instructions were given and patient was advised to report immediately in case of any emergency. Permanent restoration was done and follow up was done after 3, 6 and 9 months.

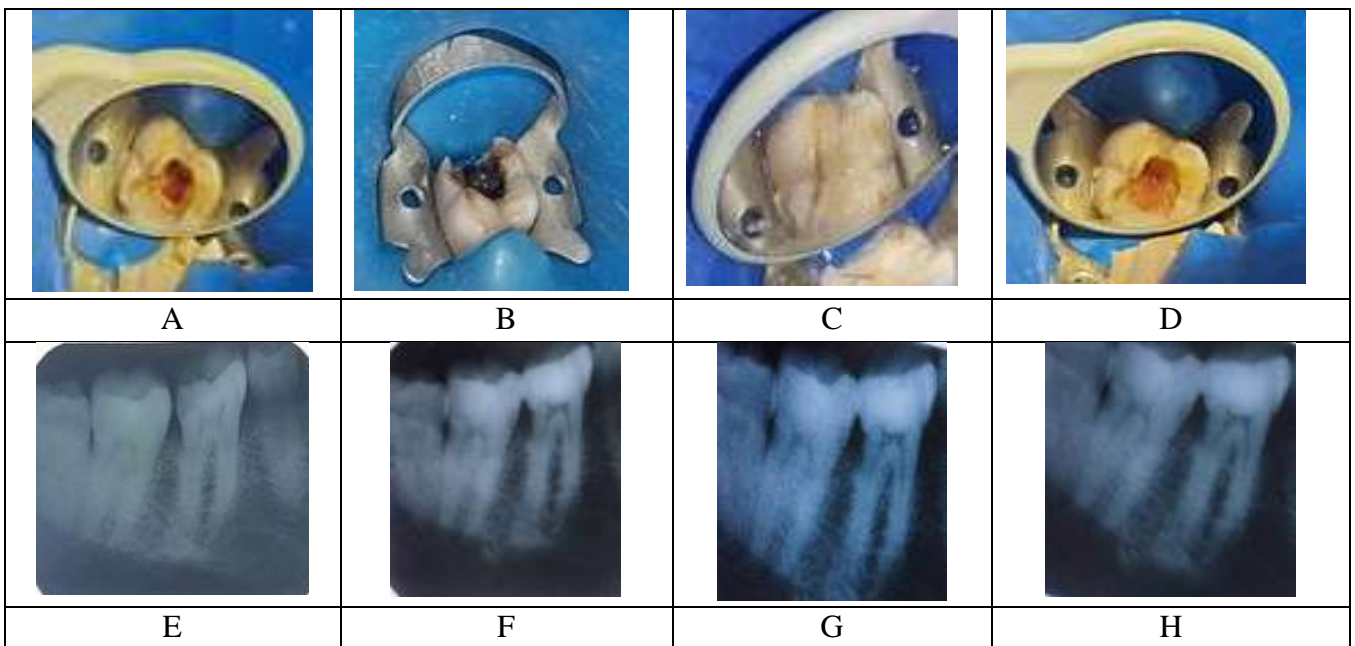


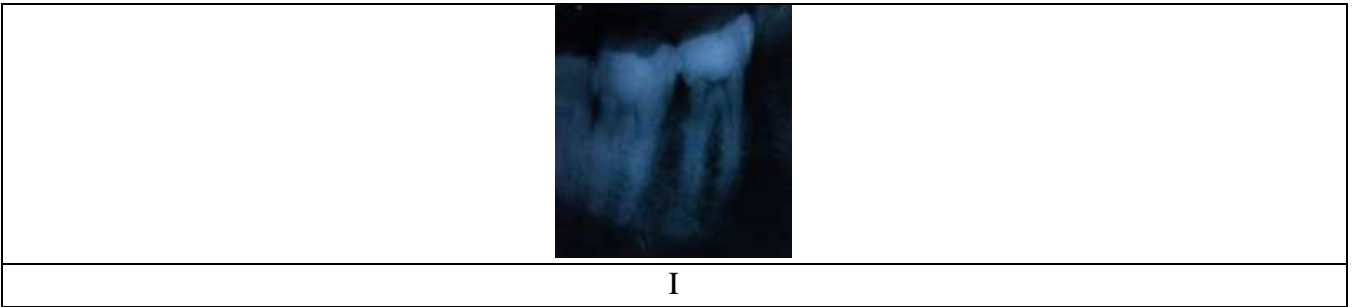a)Preoperative photograph of lower molar b) pulpotomy was done c) AM was placed id) immediate postoperative (PO)



a) Preoperative radiograph b) immediate PO radiograph c) follow up after 3 months d) follow up after 6 months e) 9 months follow up

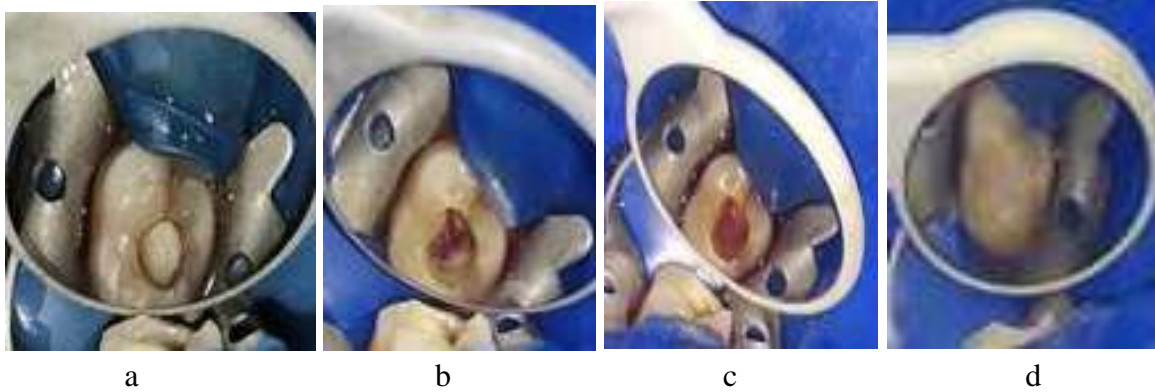
CASE 2: patient came with the history of pain and sensitivity to heat and cold since 7 days . With proper clinical and radiographic examination diagnosis of irreversible pulpitis was made and pulpotomy was planned using hAM as pulpotomy agent.



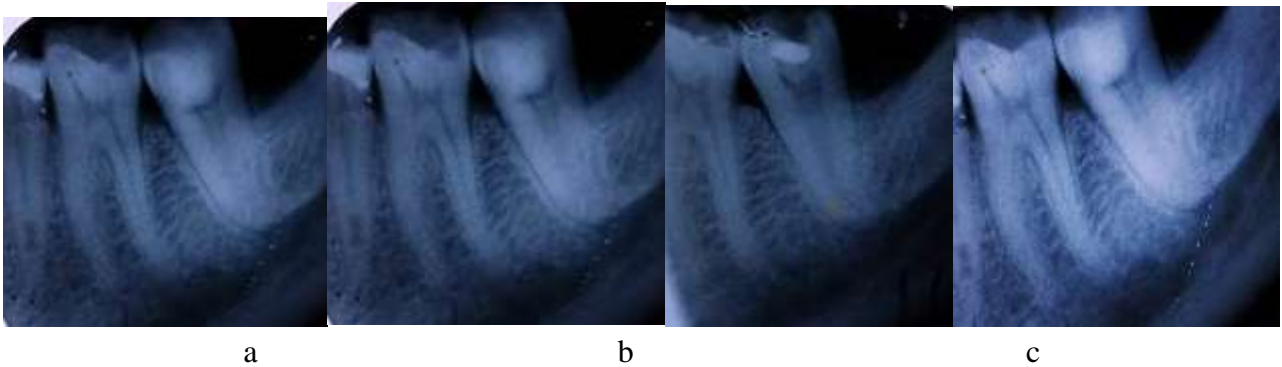


a) Preoperative clinical photograph b) pulpotomy was done c) AM was placed d) immediate PO photograph e) preoperative radiograph f) immediate PO radiograph i) 3 month follow up h) 6 months follow up i) 9 months follow up

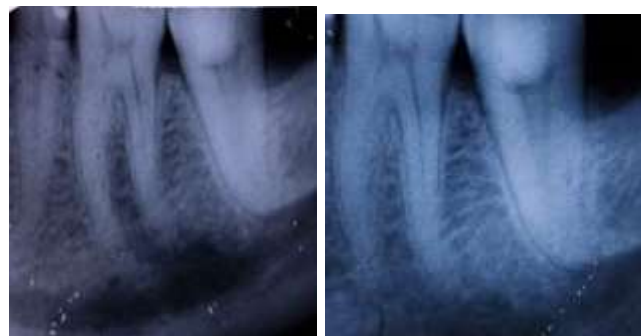
CASE 3 : patient of age 35 came with history of sensitivity to cold since 10 days in an already restored tooth. On examination dislodged restoration was found and pulpotomy was planned using h AM as pulpotomy agent.



a)Preoperative clinical photograph b) pulpotomy was done c) AM was placed d) immediate PO

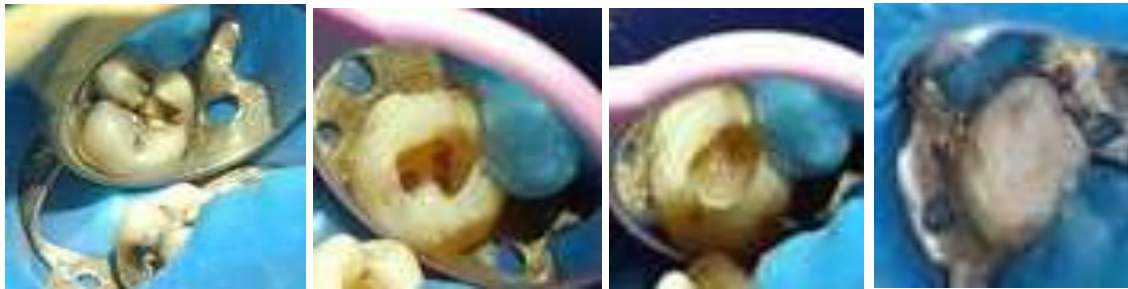


a b c



a) preoperative radiograph , b) immediate PO radiograph, c) 3 months follow up, d) 6 month follow up, e) 9 month follow up

CASE 4 : patient of age 25 yrs came with the history of pain since 2 weeks and diagnosis of irreversible pulpitis was made and pulpotomy was planned using h AM as pulpotomy agent.



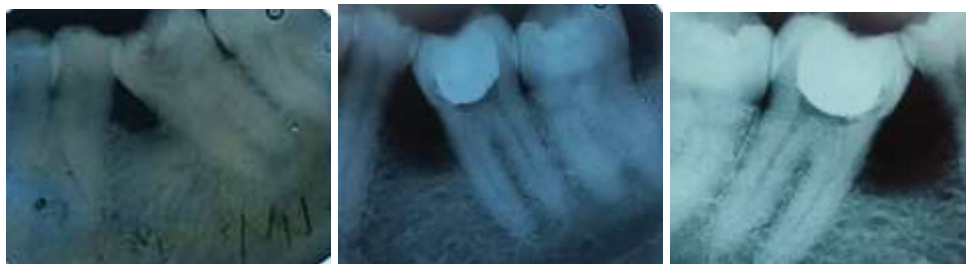a

b

c

d

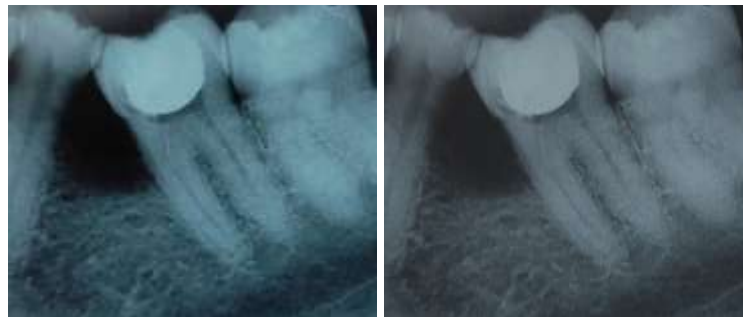
a) Preoperative clinical photograph b) pulpotomy was done c) AM was placed d) immediate PO



e

f

g



h

i

e) preoperative radiograph, f) immediate PO g) 3 months follow up, h) 6 month follow up, i) 9 months follow up

OUTCOME AND FOLLOW-UP:

The patient reported mild hot and cold sensitivity a day after pulpotomy but it subsided gradually in a week. At 3, 6 and 9 months of follow-up, the tooth was completely asymptomatic. Sensibility tests of the tooth were similar to control teeth.

DISCUSSION:

In search of ideal pulpotomy agents materials like formocresol, calcium hydroxide and other bioactive materials like MTA, bioactive glass, endosequence have been tried out with variable clinical, radiological and histological success.

The structure of hAM is similar to dental pulp tissue in several aspects. First, both of them are soft connective tissues^[3]. Second, the presence of monolayer cells in the peripheral zone, i.e., epithelial cells in hAM and odontoblasts in pulp tissue.

Cases report using AM in endodontic procedures, though very less, have been successful. Prasad et al (2021), compare AM and formocresol as a pulpotomy agent in primary molars. The results showed that AM was better than formocresol, both clinically and radiographically.

In the present study, no adjunctive material has been used along with amniotic membrane to judge its true capability as a pulpotomy agent.

AM has anti-inflammatory and has excellent revascularisation properties^[4]. Direct application of activated membrane over the amputated pulp could have promoted faster healing. As evident in our study, the pulp returned to its uninflamed, normal state. AM is readily available, cost-effective and requires no special equipment.

LIMITATIONS:

- There is always an associated risk of infection transmission.
- AM need to be dealt very carefully (as they are fragile)

CONCLUSION:

- Amniotic membrane with its ease of biocompatibility and growth factors can be use successfully as pulpotomy agent.
- Further long term studies are required to assess its success rate.

CONFLICT OF INTEREST: None

ACKNOWLEDGEMENT: The institution (H.P Government Dental College and Hospital), Shimla, India

REFERENCES

1. Mamede AC, Carvalho MJ, Abrantes AM, et al. Amniotic membrane: from structure and functions to clinical applications. *Cell Tissue Res* 2012;349:447–58.
2. Davis JS. Ii. skin grafting at the johns hopkins hospital. *Ann Surg* 1909;50:542– 9.
3. Güneş M, Altok M, Ozmen O, Umul M, Güneş A, Baş E, et al. A Novel Experimental Method for Penile Augmentation Urethroplasty With a Combination of Buccal Mucosa and Amniotic Membrane in a Rabbit Model. *Urology* 2017; 102:240–246
4. Mamede AC, Carvalho MJ, Abrantes AM, et al.. Amniotic membrane: from structure and functions to clinical applications. *Cell Tissue Res* 2012;349:447–58. 10.1007/s00441-012-1424-6 [[PubMed](#)] [[CrossRef](#)] [[Google Scholar](#)] [[Ref list](#)]