

Intravesical Migration of Intrauterine Contraceptive Devices with Calculus Formation: Two Cases and Review of Literature

Dr Vishal Naik¹, Dr Aprajita Bhandari², Dr Srinath N³, Dr Prathvi⁴

¹SR Urology, RRMCH

²JR Surgery, RRMCH

³HOD Urology, RRMCH

Abstract:

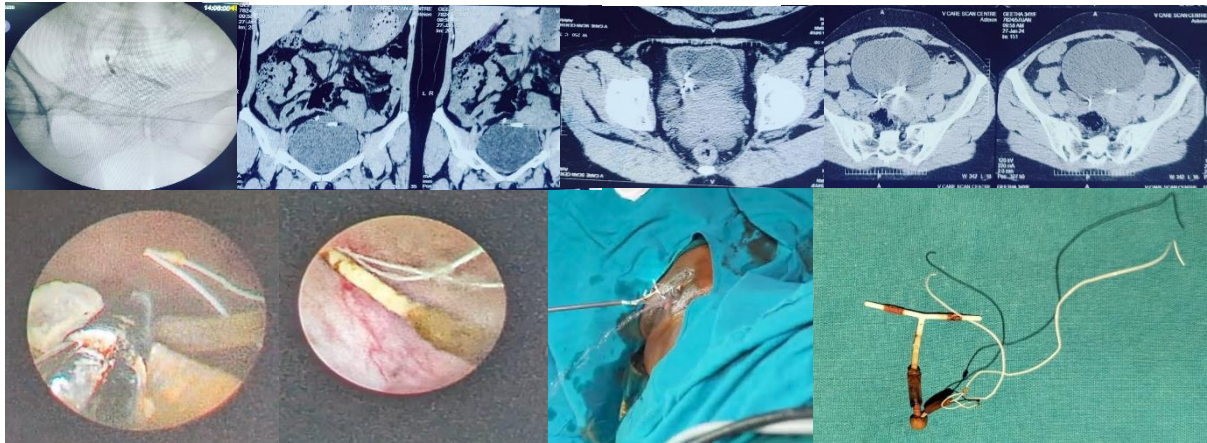
Intrauterine contraceptive devices (IUCDs) have been utilized for over five decades, with more than 100 million women worldwide employing this contraceptive method. Uterine perforation during insertion is a rare complication - occurring in approximately 0.2 to 9.6 per 1000 insertions - during which the IUD can also migrate into pelvic or abdominal organs. Instances of missing IUDs, even in the presence of pregnancy, warrant thorough investigation for uterine perforation. Discussion of potential migration into other intra-abdominal organs is imperative, particularly in cases of new onset urinary symptoms. Displaced IUDs should be promptly removed to mitigate potential complications.

INTRODUCTION

Intrauterine contraceptive devices (IUCDs) have been utilized for over five decades, with more than 100 million women worldwide employing this contraceptive method. Uterine perforation during insertion is a rare complication - occurring in approximately 0.2 to 9.6 per 1000 insertions - during which the IUD can also migrate into pelvic or abdominal organs.[\(1,2\)](#)

Case Report 1:

A 35-year-old P3L3 female presented to the OPD with chief complaints of persistent lower abdominal pain and dysuria lasting for 5 months. Her last menstrual period occurred three weeks prior to presentation. Her medical and gynaecological histories were unremarkable, except for two prior Caesarean sections. The patient had a Copper T 380 IUCD inserted during her last caesarean section 10 years ago. Upon gynaecological examination, the cervix appears closed, and the threads of the IUD were not visualised.

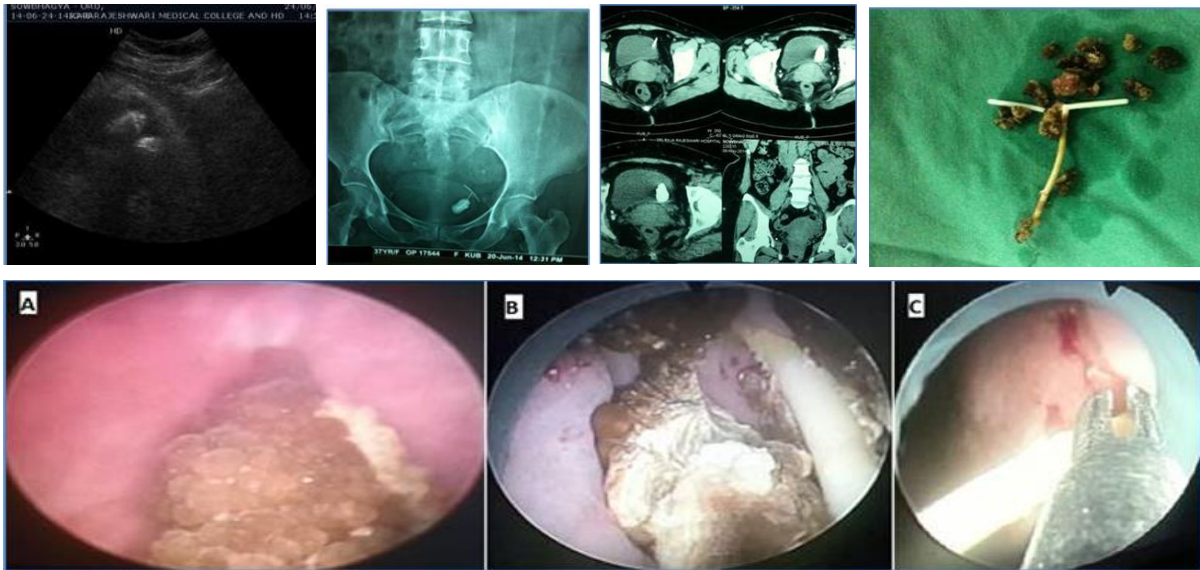


Urine routine showed 15-20 RBCs/hpf and 2-3 pus cells/hpf. Ultrasonography (USG) done elsewhere was reported as normal. However, due to ongoing and recurrent pain, a CECT scan of the abdomen and pelvis was performed, which allowed identification of the presence of an intrauterine contraceptive device (IUCD) lodged in the dome of the urinary bladder. Consequently, the patient was referred to the Urology department for further management.

Cystoscopy performed under anaesthesia, confirmed the presence of the Copper-T in the dome of the bladder, and the horizontal limb copper-T was embedded in the bladder wall with calculus formation over the vertical stem and threads of the copper T. The IUCD was safely retrieved in-toto using a crocodile grasper through cystoscopy using 24Fr Nephoscope. The calculus formed over the threads of IUCD was crushed with crocodile grasper and removed. Post-removal, a Foley catheter was kept for 3 days. The patient was discharged three days after IUCD extraction, exhibiting no postoperative complications. Patient at 3 month follow up is absolutely normal.

Case Report 2:

A 39 years old female, presented to urology OPD with complaints of intermittent lower abdominal pain accompanied with episodes of dysuria for past 12 years. She was treated for UTI on these occasions and symptoms relieved on taking medications. She had undergone intrauterine contraceptive device (IUCD) insertion 19 years back in a private clinic, after having two children. However, she conceived again one year later following IUCD insertion. The patient ignored about IUCD and failed to reveal about the same to her treating doctor. Following delivery she underwent tubectomy. On clinical examination, vitals were stable. Per abdomen examination, mild suprapubic tenderness was present. Systemic examination was within normal limits. Per vaginal examination was normal.



On ultrasound KUB, there was a hyperechoic immobile lesion in the posterior wall of bladder with post acoustic shadowing suggestive of calculus. Also, the lesion showed internal echoing and measured 3 x 4 cm. Radiologists insisted on CT KUB for determining the unusual internal echoes and immobility. On plain CT KUB, the T-tube with long limb end having calculus formed was clearly delineated. It was also noted that the short limb of T-tube was seen poking out of the bladder wall unrelated to any other surrounding structure. Urine microscopy showed pus cells and RBCs. Urine culture showed Klebsiella sensitive to Amikacin and same was initiated.

With rest of the laboratory parameters within normal limits patient was taken for surgery under spinal anaesthesia. On cystoscopy, the calculus was visible and same was broken with lithotripter using 20F amplatz sheath and 18F nephroscope. Now the IUCD was clearly visible with only the longer limb of T in the bladder around which the calculus had formed. The horizontal limb of the IUCD had buried into the bladder wall. With the long end held with grasper the T-tube was pulled out in to. However, there was no bleeding on pulling out the IUCD out of the bladder wall. A 20F per urethral Foley's catheter was inserted. Post operatively patient recovered well and was discharged after 3 days later after catheter removal. Patient was followed up for 3 years with no complaints.

DISCUSSION:

- Uterine perforation is an uncommon complication of IUD. The incidence ranges from 0.2 to 9.6 per 1000 insertions. The presence of pain and bleeding per vagina after IUCD insertion suggests that uterine perforation may have occurred at the time of insertion [9]. Secondary perforation may be due to slow migration through the myometrium which may be enhanced by spontaneous uterine contractions [10].
- Due to the asymptomatic nature of the perforation, the true incidence of the uterus perforation by an IUD is most likely higher than reported.
- The exact mechanism that causes uterine perforation and migration of the IUD is not entirely known. The most important factor related with this complication is probably the operator experience in IUD application. There are also many factors that affect uterine perforation, such as the uterine size, position, and timing of the insertion, congenital uterine anomalies and previous caesarean section.

- Patient may present with irritative voiding symptoms including frequency, dysuria, haematuria and strangury. Some patients occasionally present with no symptoms or complaint of minimal discomfort.
- Radio-opaque foreign bodies can easily be detected on KUB radiograph. X ray can be combined with ultrasonography and CT for confirmation
- When a pregnancy occurs in a patient with an IUCD, there must be a high suspicion of uterine perforation and possible migration.
- All IUCDs which have migrated into the urinary bladder must be removed even if they are asymptomatic. This is to prevent complications such as calculus formation and bladder rupture [3].
- An IUCD which has migrated into the urinary bladder is treated by cystoscopic removal or by open suprapubic cystotomy [12].
- Cystoscopic removal is preferred because it has a low morbidity and is highly effective [13]. Most of the foreign bodies in the urinary bladder can be removed endoscopically using - Biopsy forceps, grasping forceps, stone punch, glass syringe, basket or cutting loop
- Open surgery is currently restricted to centres without cystoscopic facilities and also for the removal of IUCDs with calculus formation that are not amenable to cystoscopic removal [9]. Laparoscopic removal, a minimally invasive alternative to open surgery can also be used [7].
- A foreign body in bladder initially encrust with calcium oxalate, infection, struvite deposition on nascent stone.

CONCLUSION

Instances of missing IUDs, even in the presence of pregnancy, warrant thorough investigation for uterine perforation. Discussion of potential migration into other intra-abdominal organs is imperative, particularly in cases of new onset urinary symptoms. Displaced IUDs should be promptly removed to mitigate potential complications.

REFERENCES:

1. El-Hefnawy AS, El-Nahas AR, Osman Y, et al. Urinary complications of migrated intrauterine contraceptive device. *Int Urogynecol J*. 2008; 19: 241–5.
2. Oruc S, Vatansever HS, Karaer O, et al. Changes in distribution patterns of integrins in endometrium in copper T380 intrauterine device users. *Acta Histochem*. 2005;107:95–103. [[PubMed](#)] [[Google Scholar](#)]
3. Tuncay YA, Tuncay E, Güzin K, et al. Transuterine migration as a complication of intrauterine contraceptive devices: six case reports. *Eur J Contracept Reprod Health Care*. 2004;9:194–200. [[PubMed](#)] [[Google Scholar](#)]
4. Kandirali E, Mehmet AT, Atilla S, Ahmet M. Double intrauterine device: presented with protruding stone. *Marmara Med J*. 2008;21(1):061–063. [[Google Scholar](#)]
5. Nitke S, Rabinerson D, Dekel A, Sheiner E, Kaplan B, Hackmon R. Lost levonorgestrel IUD: diagnosis and therapy. *Contraception*. 2004;69(4):289–293. doi: 10.1016/j.contraception.2003.11.017. [[PubMed](#)] [[CrossRef](#)] [[Google Scholar](#)]
6. Eke N, Okpani AO. Extrauterine translocated contraceptive device: a presentation of five cases and revisit of the enigmatic issues of iatrogenic perforation and migration. *Afr J Reprod Health*. 2003;7(3):117–123. doi: 10.2307/3583296. [[PubMed](#)] [[CrossRef](#)] [[Google Scholar](#)]

7. Farmer M, Webb A. Intrauterine device insertion-related complications: can they be predicted? *J Fam Plan Reprod Health Care R Coll Obstet Gynaecol*. 2003;**29**(4):227–231. doi: 10.1783/147118903101197854. [[PubMed](#)] [[CrossRef](#)] [[Google Scholar](#)]
8. Tosun M, Celik H, Yavuz E, Cetinkaya MB. Intravesical migration of an intrauterine device detected in a pregnant woman. *Can Urol Assoc J*. 2010;**4**(5):E141–E143. [[PMC free article](#)] [[PubMed](#)] [[Google Scholar](#)]
9. Markovitch O, Klein Z, Gidoni Y, Holzinger M, Beyth Y. Extrauterine mislocated IUD: is surgical removal mandatory? *Contraception*. 2002;**66**(2):105–108. doi: 10.1016/S0010-7824(02)00327-X. [[PubMed](#)] [[CrossRef](#)] [[Google Scholar](#)]
10. Mascarenhas MP, Tiraboschi RB, Paschoalin VP, Costa EAP, Suzuki Bellucci CH, Bessa Junior J, et al. Exercise-induced hematuria as the main manifestation of migration of intrauterine contraceptive device into the bladder. *Case Rep Urol Case Rep Urol*. 2012;2012:e736426. [[PMC free article](#)] [[PubMed](#)]
11. Priyadarshi V, Singh M, Kumar V, Tiwari R, Gupta SK, Sehgal N. An unusual cause of bladder stones in a female: a migrant intrauterine contraceptive device. *UroToday Int J* [Internet]. 2012 [cited 2015 Aug 24];05(06). http://www.urotoday.com/index.php?option=com_content&Itemid=230&catid=1356&id=54877&lang=en&view=article.
12. Dietrick DD, Issa MM, Kabalin JN, Bassett JB. Intravesical migration of intrauterine device. *J Urol*. 1992;**147**(1):132–134. [[PubMed](#)] [[Google Scholar](#)]
13. Hick EJ, Hernández J, Yordán R, Morey AF, Avilés R, García CR. Bladder calculus resulting from the migration of an intrauterine contraceptive device. *J Urol*. 2004;**172**(5 Pt 1):1903. doi: 10.1097/01.ju.0000142135.94531.bb. [[PubMed](#)] [[CrossRef](#)] [[Google Scholar](#)] Vagholkar S, Vagholkar K. Secondary vesical calculus resulting from migration of an intrauterine contraceptive device. *Case Rep Obstet Gynecol*. 2012;**2012**:603193. [[PMC free article](#)] [[PubMed](#)] [[Google Scholar](#)]
14. Rafique M. Intravesical Foreign Bodies; Review and Current Management Strategies. *Urol J*. 2008 Fall; 5 (4): 223-31.
15. Tuncay YA, Tuncay E, Guzin K, Ozturk D, Omurcan C, Yucel N. Transuterine migration as a complication of intrauterine contraceptive devices: six case reports. *Eur J Contracept Reprod Health Care* 2004; 9: 194-200.
16. Guvel S, Tekin MI, Kilinc F, Peskircioglu L, Ozkardes H. Bladder stones around a migrated and missed intrauterine contraceptive device. *Int J Urol* 2001; 8 (2): 78–79.
17. Hiller N, Zagal I, Solomom I. Intravesical foreign bodies. The danger of eroticism. *Urologia* 1999; 66: 2. 5. Calı kan E, Oztürk N, Dilbaz BO, et al. Analysis of risk factors associated with uterine perforation by intrauterine devices. *Eur J Contracept Reprod Health Care*. 2003; 8: 150