

# Left Ventricular Aneurysm Occurring At An Early Remodeling Phase After A Myocardial Infarction: A Case Report

Hanaa El Ghiati<sup>1</sup>, Fatouma Mohamed Aden<sup>2</sup>, Zouhair Lakhal<sup>3</sup>,  
Aatif Benyass<sup>4</sup>

<sup>1,2,3,4</sup>MD, Military Training Hospital of Rabat

## Abstract:

A left ventricular aneurysm (LVA) is one of the most serious complications following an acute myocardial infarction. The process leading to the formation of a ventricular aneurysm is based on the natural evolution of a transmural infarct that has been replaced by fibrous tissue. This neutral part cannot participate in contraction and herniates outwards during systole. In general, this process takes several days to develop and LVA can occur at least 48 to 72 hours after infarction. We report the case of a young patient who presented with an LVA within the first 24 hours of myocardial infarction, suggesting an early post-infarction remodeling phase. The prognosis for ventricular aneurysms is guarded. A heart team is essential for making a surgical decision.

**Keywords:** Myocardial infarction, left ventricular aneurysm, cardiac remodeling

## Introduction:

A left ventricular aneurysm is one of the worst complications after acute myocardial infarction. The natural course leading to the formation of a ventricular aneurysm involves a transmural infarct that has been replaced by fibrous tissue. This inert part is excluded from the contraction and herniates outward during systole. Generally, this process takes several days to develop and LVA can occur at least two to three days post infarction. We report a case of a young patient who presented with LVA occurring at the first 24 hours of a myocardial infarction suggesting an early post-infarct remodeling phase.

## Case report:

A 49 years-old patient, with recent diabetes as a cardiovascular risk factor, presented to the emergency department with an epigastric pain and shortness of breath. Cardiovascular examination revealed heart rate at 133bpm, respiratory rate 24, blood pressure at 106/69, normal heart sounds. Lungs examination showed bilateral crackles. Biological exams revealed an inaugural diabetic ketoacidosis.

Initial electrocardiogram showed a sinus rhythm interspersed with multiple monomorphic premature ventricular contractions with long coupling interval followed by compensatory pause. The normal complexes showed an ST elevation in the anterior leads from V1 to V6 and D1, aVL. (Figure 1)

Another electrocardiogram was performed noted Q waves and persistent ST segment elevation in the anterior leads. (Figure 2)

Chest radiograph showed ventricular enlargement, cardiomegaly and hilar overload. (Figure 3)

A transthoracic echocardiogram demonstrated an ischemic cardiomyopathy with severe regional wall motion abnormality with akinesia over the apex and adjacent walls, inferoseptal, anteroseptal, inferolateral and inferior associated with hypokinetic anterolateral wall; with severe left ventricle dysfunction (left ventricle ejection fraction of 20% GLS of -8.2%). It also showed a left ventricular aneurysm over the septal wall with a broad neck and spontaneous contrast suggesting a prethrombotic aspect. A pericardial effusion was also noted (Figure 4).

Cardiac catheterization with coronary angiography was performed using a right femoral artery approach showed a sub occlusive lesion of the left anterior descending artery in its proximal and middle segment with thrombolysis in myocardial infarction (TIMI) grade two flow (Figure 5).

MRI was performed to look for viability in the territory of the anterior interventricular artery. It showed necrosis in the territory of the right interventricular artery, which is not viable (Figure 6).

An optimal treatment of ischemia and heart failure was instated including 75mg of clopidogrel and aspirin, 2mg of acenocoumarol. An optimal dose of bisoprolol, ivabradine and dapagliflozine was administered after stabilization. Furosemide, ramipril and spironolactone were prescribed for his left heart dysfunction.

The patient was implanted with a defibrillator-cardioverter device. A 3 years follow-up showed an asymptomatic patient with good evolution.

### **Discussion:**

Left ventricular aneurysm is known to be one of the most dangerous consequence of coronary heart disease, [1]. More than 95% of LVAs reported in the literature resulted from MI secondary to coronary artery disease; especially in those where the infarct is transmural[2].

The first step in diagnosing a LVA is to know if it's a true or false one. A true LVA involves the entire LV wall thickness and protrudes. A false LVA follows rupture of the ventricular wall, is contained by the surrounding pericardium, and often occurs 5 to 10 days after left circumflex coronary artery occlusion. In our case, the patient presented with a true LVA based on its wide collar and the involvement of the whole septal wall.

In 90% of cases, the LVA is located at the apex of the heart or in the anterior wall, and in 10%, it is in the posterior-inferior wall [3]. Our patient's LVA was taking the middle and apical segment of inferior and inferoseptal wall.

It is proved that myocyte death begin within 20 minutes in some experimental studies involving dogs with transmural MI and no collateral circulation, [4] Within a few days, the endocardial wall become smooth and thin and fibrosed. This may explain the early remodeling phase leading to the early constitution of the LVA within the first 24 hours in our case. In fact, our patient was young and had presented with an inaugural epigastric pain, therefore had a very poor collateral circulation.

The constitution of LVA secondary to transmural necrosis generally had two main phases: early expansion and subsequent remodeling. The early expansion occurs in the area of the MI, while the remodeling phase affects the muscle fiber cells, leading to fibrosis and changes in the geometry of the ventricular cavity [5]. These changes result in progressive ventricular dilation, increased wall tension, and altered systolic function, leading to irreversible contractile dysfunction. The early expansion happened too fast in our case leading particularly to rapid left ventricular remodeling, thus the constitution of the LVA.

Left ventricular aneurysms occur after MI when the left anterior descending coronary artery (LAD) becomes completely occluded, and collateral circulation within the ischemic myocardium is poor [6]. Rarely, LVAs occur in the presence of multivessel disease and extensive collateral circulation [7]. In our case, the culprit lesion interested the LAD only with no affection of the rest of the coronary arteries.

As LVA is responsible of volume overload in the LV and the increase in oxygen consumption, angina is its most prevalent symptom [8]. Any functional mitral regurgitation can exacerbate ventricular overload, progressively leading to the onset of heart failure. Dyspnea, the second most frequent symptom, occurs because of a combination of systolic and diastolic dysfunction. In a matter of fact, our patient presented with a congestive heart failure. In more than one third of patients, atrial or ventricular arrhythmias cause palpitations, syncope, or sudden death, or they exacerbate angina and dyspnea [8]. Premature ventricular contractions were present in the admission's EKG only and the patient had evolved well after having the optimal dose of bisoprolol.

Left ventriculogram can also be used to identify LVA [9]. Two-dimensional echocardiography is the most used tool and can be sufficient to reveal LVA, identify a mural thrombi and mitral valve regurgitation. The echocardiogram of our patient showed a pre-thrombotic aspect in the LVA, indicating an anticoagulant therapy. Computed tomography and magnetic resonance imaging can also be used to identify aneurysms [8].

The presence of LVA alone is not a surgical indication. Surgery is indicated when concomitant, persistent angina, refractory heart failure, thromboembolism, or life-threatening tachyarrhythmias occur [10]. Myocardial revascularization is typically performed at the time of aneurysmectomy. The inhospital mortality rates for patients undergoing these procedures range from 2% to 19%, with a mean of approximately 10% [11]. Risk factors for early death include severe LV failure, MI, and intractable arrhythmias. Risk factors for late death include incomplete revascularization and reduced systolic function of the basal segments of the LV and the interventricular septum[11].

The severe LV failure of our case, the myocardial infarction and ketoacidosis decompensation had unfortunately worsened the prognosis of the LVA. Revascularization was not indicated due to the lack of the viability of the affected ventricular walls, nor the aneurysmectomy. Our patient was under optimized medical treatment involving dapagligozine, angiotensin receptor neprilysin inhibitor, maximal dose of betablocker and DAPT. In addition, the patient was implanted with cardioverter-defibrillator device. The patient was stabilized under this treatment with less dyspnea and no history of recurrent angina.

### **Conclusion:**

Left ventricular aneurysm is one of the most critical complications of myocardial infarction. It rarely happens during the first 24hours postinfarction especially when there is a poor collateral circulation and an important transmural necrosis. The prognosis of ventricular aneurysms is reserved. An interprofessional heart team is fundamental to make a surgical decision.

**Availability of Data and Materials:** Data sharing is not applicable to this article as no datasets were generated or analyzed during the current study.

**Acknowledgments:** None

**Conflict of interest:** None

**Sources of funding:** None

**Ethical approval:** N/a

**Consent:** Written informed consent was obtained from the patient for publication of this case report and accompanying images. A copy of the written consent is available for review by the Editor-in-Chief of this journal on request.

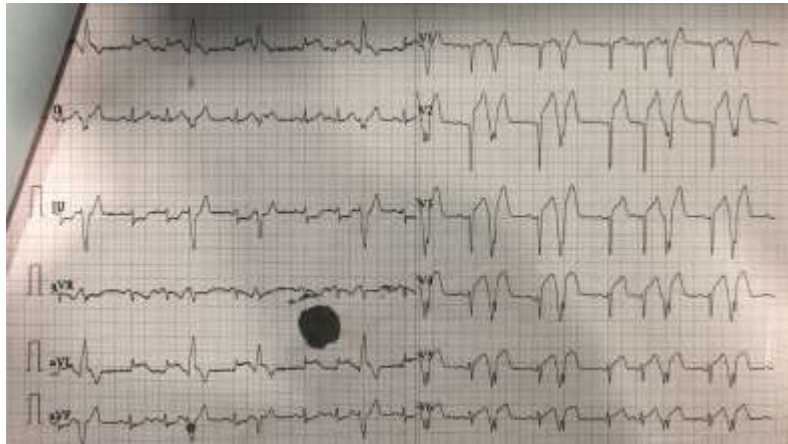
**Research registration:** N/a

**Provenance and peer review**

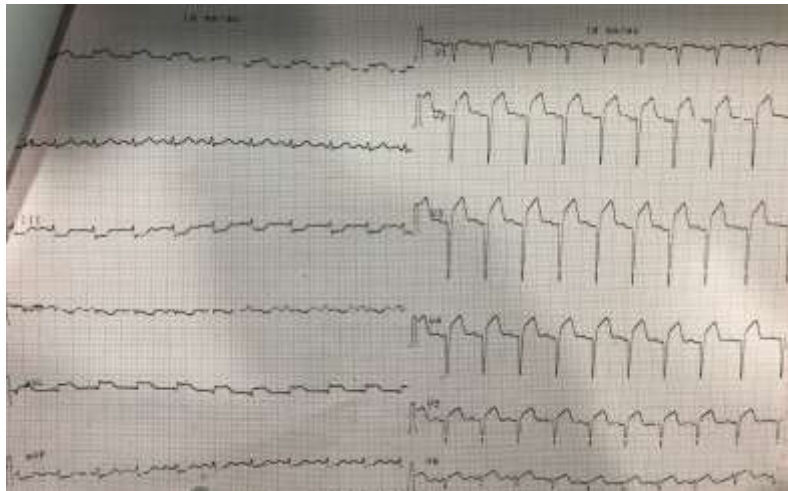
**Not commissioned, externally peer-reviewed**

### References:

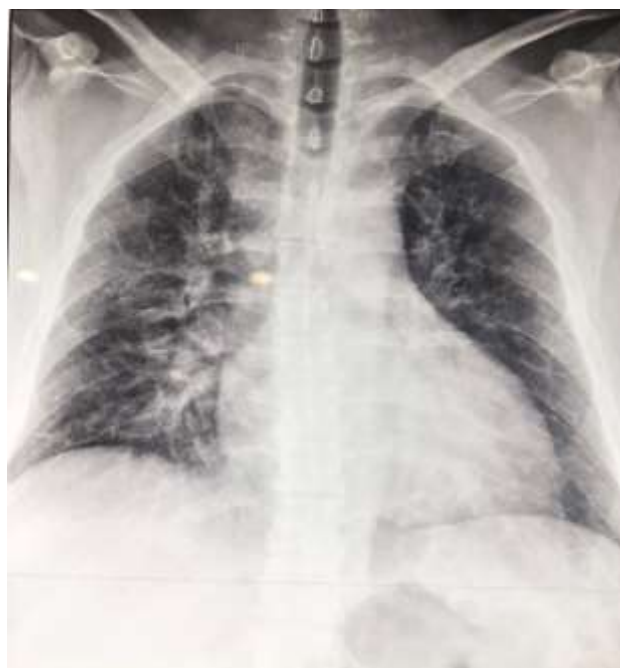1. Schuster EH, Bulkley BH. Expansion of transmural myocardial infarction: a pathophysiologic factor in cardiac rupture. *Circulation*. 1979;60(7):1532–8.
2. Mills NL, Everson CT, Hockmuth DR. Technical advances in the treatment of left ventricular aneurysm. *The Annals of thoracic surgery*. 1993;55(3):792–800.
3. ABRAMS DL, Edelist A, LURIA MH, MILLER AJ. Ventricular aneurysm: a reappraisal based on a study of sixty-five consecutive autopsied cases. *Circulation*. 1963;27(2):164–9.
4. Glower DD, Schaper J, Kabas JS, Hoffmeister HM, Schaper W, Spratt JA, et al. Relation between reversal of diastolic creep and recovery of systolic function after ischemic myocardial injury in conscious dogs. *Circulation research*. 1987;60(6):850–60.
5. Gerdes AM, Capasso JM. Structural remodeling and mechanical dysfunction of cardiac myocytes in heart failure. *Journal of molecular and cellular cardiology*. 1995;27(3):849–56.
6. KANAZAWA T. Coronary collateral circulation: its development and function. *Japanese circulation journal*. 1994;58(3):151–65.
7. Meizlish JL, Berger HJ, Plankey M, Errico D, Levy W, Zaret BL. Functional left ventricular aneurysm formation after acute anterior transmural myocardial infarction: incidence, natural history, and prognostic implications. *New England Journal of Medicine*. 1984;311(16):1001–6.
8. Ruzza A, Czer LS, Arabia F, Vespignani R, Esmailian F, Cheng W, et al. Left ventricular reconstruction for postinfarction left ventricular aneurysm: review of surgical techniques. *Texas Heart Institute Journal*. 2017;44(5):326.
9. Kajita AH, Oliveira MDP, Menezes FR, Franken M, Baracioli LM, Nicolau JC. Giant and Calcified Post-Infarction True Left Ventricular Aneurysm: What to Do? *Arquivos brasileiros de cardiologia*. 2016;106(3):259–62.
10. Grondin P, Kretz JG, Bical O, Donzeau-Gouge P, Petitclerc R, Campeau L. Natural history of saccular aneurysms of the left ventricle. *The Journal of thoracic and cardiovascular surgery*. 1979;77(1):57–64.
11. Cosgrove D, Lytle B, Taylor P, Stewart R, Golding L, Mahfood S, et al. Ventricular aneurysm resection. Trends in surgical risk. *Circulation*. 1989;79(6 Pt 2):I97-101.



**Figure 1 : Electrocardiogram showing premature ventricular contractions**

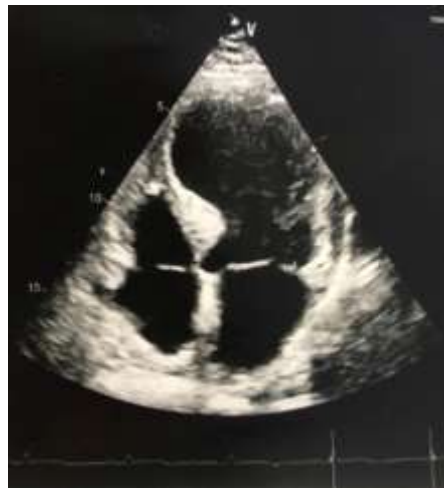

**Figure 2 : Electrocardiogram showing Q waves with ST elevation in the anterior leads**

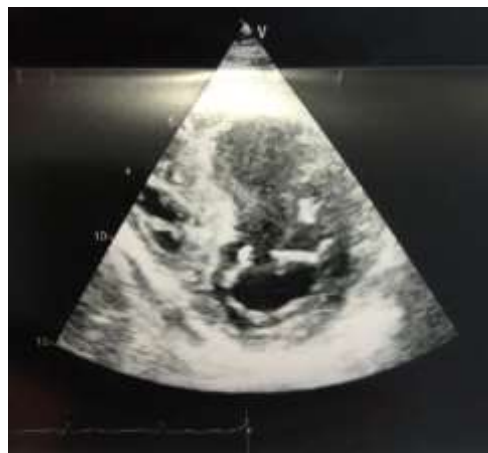

**Figure 3 : chest radiography showing cardiomegaly with hilar congestion**

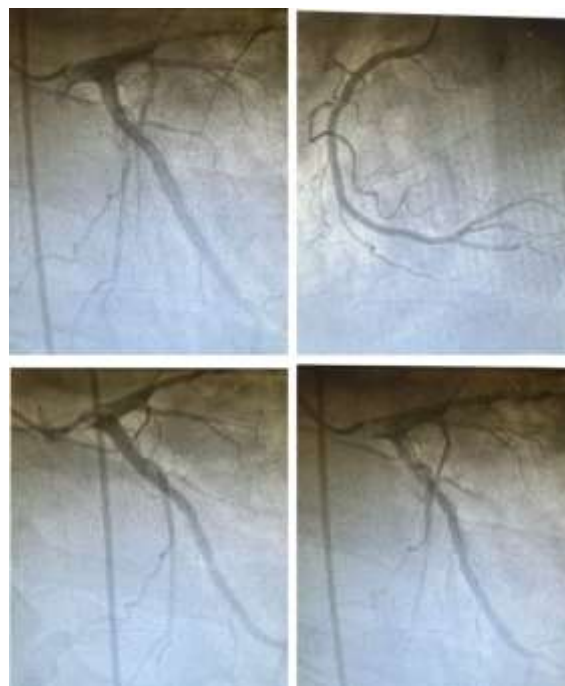




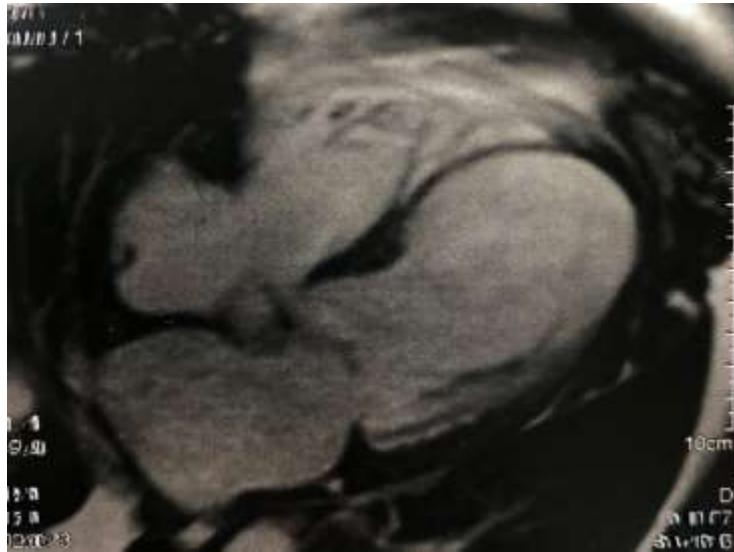**Figure 4 : Apical 4 chambers showing wide neck inferoseptal wall**



**Figure 4': short parasternal axis showing a true septal aneurysmal of the left ventricle**



**Figure 5: Cardiac catheterization showing a subocclusive left anterior descending artery**



**Figure 6: The presence on MRI of necrosis in the territory of the right interventricular artery, which is non-viable**